



## A HUGE OVARIAN SEROUS CYSTADENOMA: A CASE REPORT

Dr. Preshi Pant\* and Prof. Dr. Yi Cun Jia

*Department of Gynaecology and Obstetrics, The first affiliated Hospital of Yangtze University, Jingzhou, Hubei Province, P.R. China.*

### ABSTRACT

**Objectives:** To report the occurrence of a huge benign ovarian tumor (serous cystadenoma) in Jingzhou city, Hubei, China.

**Patients:** Our reported case was an elderly woman presented with lower abdominal pain, distension and discomfort at our hospital.

**Methods:** The data were collected by history taking, clinical examinations, laboratory investigations, transabdominal ultrasonographic examination, MRI and by histopathological study of the surgically excised specimen.

**Results:** The case was reported as a huge ovarian serous cystadenoma.

**Conclusions:** This case report emphasizes the significance of thorough evaluation of all women presented with simple abdominal pain. Although the condition is common, it is a potentially dangerous in its massive form if not timely diagnosed and managed properly. With the increasing awareness of such conditions, more and more cases could be detected and reportedly early.

**Key words:** Ovarian tumor, serous cystadenoma, Huge size, TAH, BSO

## INTRODUCTION

Ovarian tumors have been classified into three main groups: epithelial, stromal and germ cells tumors on the basis of their origin. Among them the epithelial tumors are the most common type accounting for about 60% of all the ovarian tumors in adult [1]. Benign cystic teratoma has been regarded as a single most common benign ovarian neoplasm but some studies have shown serous cystadenoma as the common one [2]. Serous and mucinous tumors are the most common epithelial tumors occurring in women at age group 60-70 years [1]. Serous tumors develop from the totipotent surface epithelium of ovary and they secrete serous fluid. Serous tumors are generally benign; 5-10% has borderline malignant potential, and 20-25% are malignant [3]. Most common presenting features of serous tumors are abdominal pain, discomfort and abdominal distension. We present a case of a huge ovarian serous cystadenoma weighing 6.3 Kg which was benign in nature.

## CASE REPORT

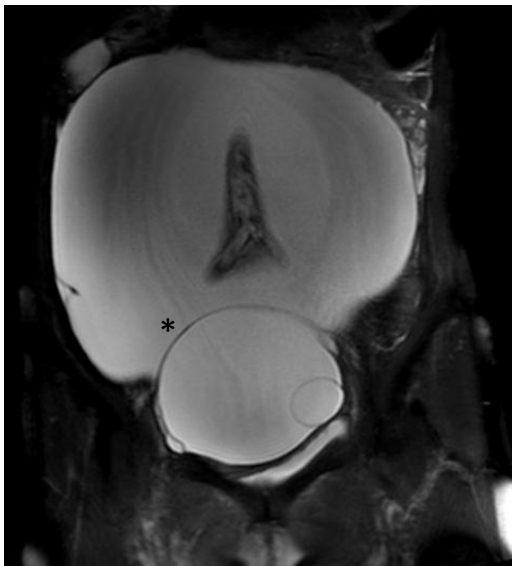
A 66 years female patient was presented in our hospital with the history of lower abdominal pain for 3 days and lower abdominal discomfort on and off since 20 years. She gave the history of abdominal distension since 2 years and also mentioned about intermittent lower abdominal pain which resolved on its own since 3 months. She also gave the history of menopause for more than 10 years and has no any abnormal vaginal bleeding since then. She didn't give any history of significant weight loss and had normal bowel-bladder habit. On her past history, she had tuberculosis 30 years back for which she didn't receive systematic treatment. She also mentioned about typhoid and schistosomiasis which was cured. She didn't give any history of diabetes, hypertension, asthma, blood disorders, drugs or food allergy. She gave the history of enteroscopy in 2015 and no any other surgical interventions. She has no history of blood transfusion and her immunization status was unknown. She gave the history of smoking and drinking alcohol in past but left since 5 years. She has no history of drug abuse or any contact with radio-active substances and chemical poisons. She got married at the age of 24 years and bore 2 children normally and aborted one. Her father is still alive and mother died due to stroke.

On physical examination, her temperature was recorded to be 36.6°C, pulse-64b/m, respiratory rate-20 br/m, BP-100/60mm of Hg. Her body development looked normal, had normal nutritional status, round face, independent decubital status and patient was co-operative. She was pale, non-icteric, non-cyanotic, no clubbing, no spider nevus, no any lymph node enlargement and bilateral thyroid glands were intact. The heart rate, rhythm was regular with no any pathological murmur and bilateral breathe sounds were clear. Abdominal wall was soft, mildly tender and mass was palpable on lower abdomen above the height of umbilicus. Bilateral upper and lower limb movement was intact and physiological reflex existed and pathological reflex was non-elicited. On vaginal examination she had senile type vulva, smooth vagina with

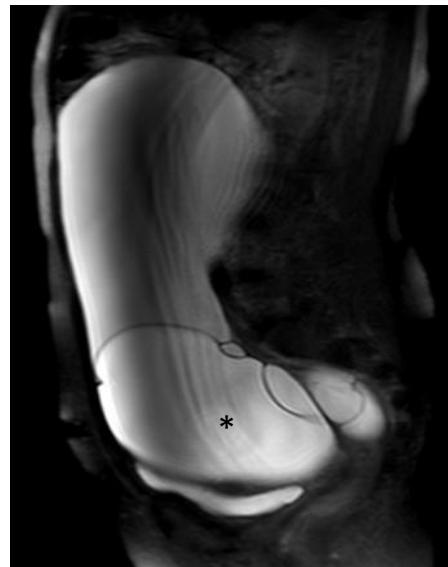
few white secretions, atrophied cervix, non-palpable uterus, huge mass of size of about 30 weeks was palpable which was soft, mobile and smooth surfaced. Pre-operative investigations including liver and renal functions were normal. CEA was 3.46ng/ml and CA125 was 25.1U/ml.

On ultrasound examination, the uterus was atrophic and separate from the mass. Large anechoic area of size 34.5cm\*11.8cm with clear boundary was seen in the pelvic cavity. There was no obvious abnormal blood flow in CDFI. Uterine appendages were not clearly visible. Pelvic cystic mass; mucinous cystadenoma was suspected.

Magnetic resonance imaging confirmed the diagnosis of left ovarian cyst with multiple septations. Laparotomy was done. Abdomen was opened by a vertical midline incision extending above the level of the umbilicus. A tensed and glistening smooth surfaced cystic mass measuring of about 35cm in diameter occupying the pelvic cavity was noted. The mass originated from the left ovarian region, and was connected by a small pedicle. Cystic fluid was clear and devoid of substances. Uterus was atrophied. The left fallopian tube was adherent, thinned out and stretched over the surface of the cyst. There was no free fluid in the abdomen. The cyst was initially drained and multiple loculated lesions were seen, then the sac was excised. Total abdominal hysterectomy with bilateral salpingo-oophorectomy was done. Both tubes and ovaries and the uterus were healthy.

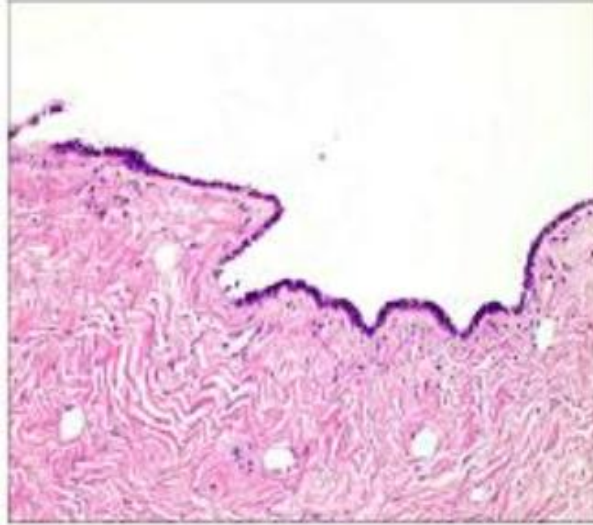


**Figure 1**



**Figure 2**

T2W MR Images of benign serous cystadenoma demonstrating multilocular cystic mass with areas of high signal intensity in the pelvic cavity. Figure 1 shows coronal view of the cyst(\*), Figure 2 shows sagittal view of the cyst(\*)



**Figure 3:** Image of the specimen's histopathological slide showing benign serous cystadenoma with simple columnar epithelial lining, no atypia, no invasion is seen.

On histopathology, the section of the cyst was thin walled and lined by columnar epithelium and stroma contained fibroblasts. Nuclear atypia and increased mitotic index were not observed suggestive of benign serous cystadenoma. The sections from the uterus, tubes and the ovaries were normal. Post operative period was uneventful and patient was discharged on 9th post-operative day. The patient is on regular follow up and has no problem till date.

## DISCUSSION

These days incidence of giant ovarian tumors have become rare in our clinical practice as most of the cases are diagnosed earlier due to increased awareness among general people as well as with the advancement of imaging modalities [4]. Discovering of cysts in the pelvic region has become a matter of worry for women. They fear whether the cysts have the potential of becoming malignant and ruining their life, but fortunately the majority of ovarian cysts are benign in nature.

Serous cystadenoma is a benign ovarian tumor. It is an uncommon ovarian tumor in adolescent age group and rare in children. They are the most common tumor in women at fourth or fifth decades of life. Ovarian serous cystadenoma primarily occurs unilaterally [5, 6]. About 15-25% occur bilaterally and about 20-25% are malignant. Ovarian serous cystadenoma, on the basis of the amount of fibrous tissue, can be classified into 6 types; cystadenoma, cystadenofibroma, adenofibroma, papillary cystadenoma, papillary cystadenofibroma and papillary adenofibroma. Serous cystadenoma are usually oval or round, multilocular or unilocular, ranging from 3-10cm in diameter, with a gray coloured, shiny surface and cystic fluid is clear to yellowish in colour, rich in serum proteins-albumin and globulin. The fluid is devoid of any substance

particles in it. If the cyst is left untreated, it may grow to a massive size and may cause life threatening complications like ovarian torsion. Microscopically, they have a single layer of ciliated simple columnar or non-ciliated simple cuboidal epithelium. Sometimes surface papillary projections or growth may be seen which may be so prolific that the cyst may look solid and stroma has varying degree of fibroblasts in it. Psammoma bodies; tiny, spherical, laminated calcified structures may be present in about 15% of the cases. Cellular atypia, complexicity or tissue invasions can't be seen at all.

Royal college of obstetrician and gynaecologists(RCOG) of UK have published guidelines to manage the ovarian cysts in postmenopausal women. Assessment for hemodynamic instability would be the initial step in evaluation following the assessment of clinical signs and symptoms. A thorough medical history should be taken from the woman, with specific attention to risk factors and symptoms suggestive of ovarian malignancy and a family history of ovarian, bowel or breast cancer. A full physical examination of the women is essential and should include abdominal examination to detect ascites and characterize any palpable mass and vaginal examination. Beside the routine lab investigations, CA125 should be the only serum tumor marker used for primary evaluation as it allows the Risk of Malignancy Index (RMI) of ovarian cysts in postmenopausal women to be calculated. Other supportive tumor markers may be CEA, CA19-9, AFP, LDH, HE4 with additional laboratory investigations as needed. Abdominal and pelvic ultrasound (transvaginal and transabdominal) as well as CT and MRI are important imaging modalities for the diagnosis of the mass and assess its size, complexicity and locatioin of pathology. Generally in USG, ovarian serous cystadenoma is usually seen as unilocular cystic/anechoic adenexal lesions. Sometimes septations may be seen in some lesions. In CT scan the cyst is often seen as unilocular or multilocular mass with homogenous CT attenuation, with a thin regular wall or septum, and usually no endocystic or exocystic vegetation [7, 8]. The typical findings in MRI of serous cystadenoma may be unilocular thin walled adenexal cyst [9]. It may show a beak sign which may suggest an ovarian origin. In T1W image the cyst gives hypointense signal intensity, in T2W images, it gives hyperintense signal intensity and T1W contrast images may give enhancement of cyst wall. Usually, CT should not be included in routine test and should be done if malignancy is suspected whereas MRI should be used as the second line imaging modalities for the characterization of indeterminate ovarian cysts when ultrasound is inconclusive. In resource limited environment, serum CA125 and ultrasonography are useful tools for screening, preoperative diagnosis and monitoring of therapy [10, 11]. Management of the cyst is done on the basis of the size of the cyst and RMI. If RMI is < 200 and the cyst is asymptomatic, simple, unilocular, unilateral and size is small (<5cm), conservative management should be considered and assessment should be repeated after 4-6 months. Similarly, if RMI is <200 and cyst has any of the features like cyst size is >5cm, cyst is complex or multilocular or bilateral or symptomatic, then, surgery; bilateral salphingo-oophorectomy(BSO) should be done. In case of RMI >200, the case is further evaluated with CT scan and management is carried out on the basis of its findings.

In our case, the RMI was less than 200, the cyst was oval in shape, size of the cyst was huge, it was

complex, multiloculated and unilateral. Since, the uterus was atrophied and the patient was senile, with the positive consent of the patient, total abdominal hysterectomy with bilateral salpingo-oophorectomy(TAH+BSO) was done.

## CONCLUSION

We presented a case of huge ovarian serous cystadenoma in an elderly patient which has been rare these days due to great success achieved in the context of imaging modalities. In our case, the patient was brought to our hospital and received the appropriate treatment timely but had it been later, numbers of life threatening complications could have posed big challenges in the successful management of the patient. The size of the cyst was the largest ever reported in our hospital.

## Abbreviations:

RMI- Risk of Malignancy Index, CEA- Carcinoembryonic antigen, CA125- Cancer antigen 125, AFP- Alphafetoprotein, LDH- Lactate dehydrogenase, HE4- Human epididymis secretory protein 4, CDFI- Color Doppler flow imaging, TAH- Total abdominal hysterectomy, BSO- Bilateral salpingo-oophorectomy.

## REFERENCES

1. Dhillon, P.K., et al., *Trends in breast, ovarian and cervical cancer incidence in Mumbai, India over a 30-year period, 1976-2005: an age-period-cohort analysis*. Br J Cancer, 2011. **105**(5): p. 723-30.
2. Mulayim, B., et al., *Unaware of a giant serous cyst adenoma: a case report*. Arch Gynecol Obstet, 2006. **273**(6): p. 381-3.
3. Dey, M. and N. Pathak, *Giant serous papillary cystadenoma*. Med J Armed Forces India, 2011. **67**(3): p. 272-3.
4. Menahem, S. and P. Shvartzman, *Giant ovarian cyst mimicking ascites*. J Fam Pract, 1994. **39**(5): p. 479-81.
5. Diamantopoulou, S., et al., *Serous cystadenoma with massive ovarian edema. A case report and review of the literature*. Clin Exp Obstet Gynecol, 2009. **36**(1): p. 58-61.
6. Sujatha, V.V. and S.C. Babu, *Giant ovarian serous cystadenoma in a postmenopausal woman: a case report*. Cases J, 2009. **2**: p. 7875.
7. Jung, S.E., et al., *CT and MR imaging of ovarian tumors with emphasis on differential diagnosis*. Radiographics, 2002. **22**(6): p. 1305-25.
8. Jeong, Y.Y., E.K. Outwater, and H.K. Kang, *Imaging evaluation of ovarian masses*. Radiographics, 2000. **20**(5): p. 1445-70.
9. Imaoka, I., et al., *Developing an MR imaging strategy for diagnosis of ovarian masses*. Radiographics, 2006. **26**(5): p. 1431-48.
10. Jelovac, D. and D.K. Armstrong, *Recent progress in the diagnosis and treatment of ovarian cancer*. CA

Cancer J Clin, 2011. **61**(3): p. 183-203.

11. Nguyen, L., et al., *Biomarkers for early detection of ovarian cancer*. Womens Health (Lond), 2013. **9**(2): p. 171-85; quiz 186-7.