



CASE PRESENTATION OF ST SEGMENTS ELEVATION IN LEAD AVR: ELECTROCARDIOGRAPHIC AND ANGIOGRAPHIC FINDINGS

Dr. Sudarshan subedi^{1*} and Prof. Dr. Yang Shaning²

¹Department of Cardiology, The first affiliated Hospital of Yangtze University, Jinzhou 434023, China

²Department of Cardiology, clinical college of Yangtze University, The first affiliated hospital to Yangtze University, Jinzhou, P.R China

ABSTRACT

A 62-year-old-female patient with no previous medical history presented with oppressive chest pain; initial electrocardiogram showed ST segment elevation in aVR and V1. Emergent coronary angiogram showed a mid-segmental occlusive stenosis of the left anterior descending artery, left circumflex and right coronary artery and the patient was hemodynamically unstable during the first 72 hours. Insights into the significance of ST segment elevation in aVR are presented and discussed in current medical scenario.

Keywords: ST elevation, aVR, V1, acute coronary syndrome

INTRODUCTION

Augmented vector right (aVR) lead is commonly “ignored” and designated as the “neglected lead”.[1] In the setting of acute coronary syndrome, severe left main coronary artery disease usually presents as widespread ST segment depression, whereas ST segment elevation (STE) in aVR (STE-aVR) is a less recognized finding.[2] More importantly, STE-aVR can also manifest in left anterior descending (LAD) artery occlusion/sub-occlusion and it is also an uncommon electrocardiographically sign in this setting.[3]

Case presentation:

A 62 –year-old female presented to the emergency department complaining of persistent chest pain. She reported experiencing sweating with increasing dyspnea associated with squeezing nature of chest pain at rest over the past 2 hours. Her past medical history is not significant for any cardiovascular risk factors. Physical examination at arrival showed a heart rate of 80 bpm, temperature 36.5 degree Celsius, a respiratory rate at 20/min, and a blood pressure of 130/80 mmHg.

Initial electrocardiogram (Fig.1A) showed, STE-aVR [J elevation, >0. 1mv; horizontal STE, 2mm]; Hence, patient was given aspirin 300mg loading dose and enoxaparin 1mg/kg in ER and she was admitted to CCU for further monitoring. After 6 hrs. of admission electrocardiogram was repeated (Fig.2) showed QS pattern from V1 until V4.

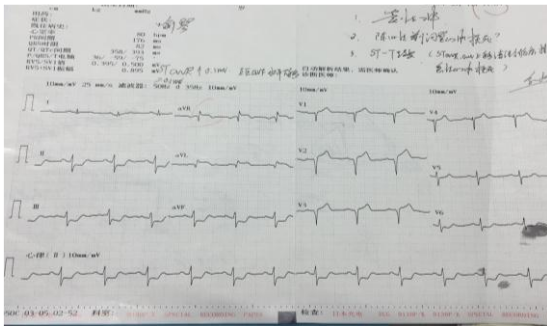


Figure 1A: Electrocardiogram at presentation

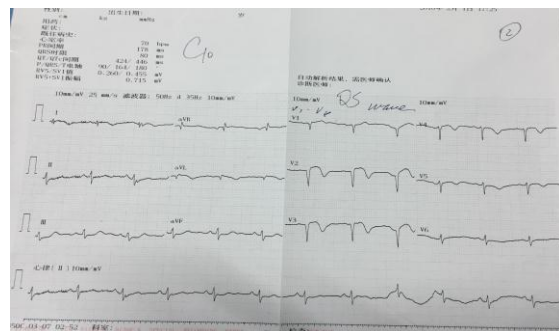


Figure1B: Electrocardiogram after 6 Hours of admission

An emergent coronary angiogram (Fig.3a &3b.) showed mid-segment occlusion of LAD stenosis (100%), with TIMI antegrade of dye 0; additionally, there was 99% stenosis with TIMI blood flow II in the left circumflex artery and >90% mid-segment diffuse stenotic lesion in the right coronary artery; PDA=80%.

- 1) Angioplasty first done in Left circumflex artery (LCA), using 6F EBU 3.0 guiding catheter. Then used maverick dilatation balloon catheter of measuring 2.0 / 20 mm and dilated at 12 atm pressure. Then we deployed Endeavor Resolute drug eluting stent measuring 2.25 /18 mm Blood flow TIMI 1 before and

after PCI TIMI 3.

- 2) Angioplasty in Left Anterior Descending Artery (LADA),using Pilot 50 guiding wire Pilot 50 guide wire is passed through the catheter.we deployed Endeavor Resolute DES measuring 2.25/ 30 mm at 8 atm pressure distally and at the proximal part Firebird DES measuring 2.5/33 mm and dilated at 14 atm.Before TIMI Score was 0, After PCI Timi score is 3.
- 3) RCA was left as it was.

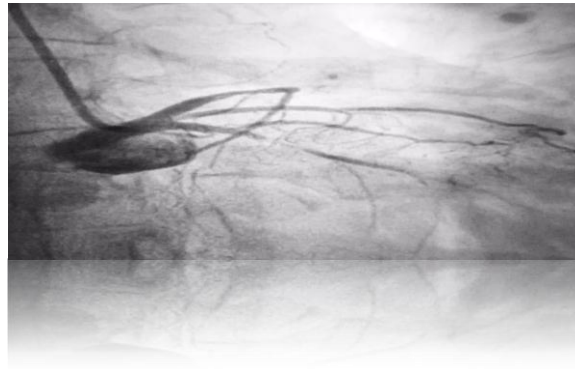

Figure 3A: Coronary angiogram showing a stenosis on LCA and proximal stenosis on LADA

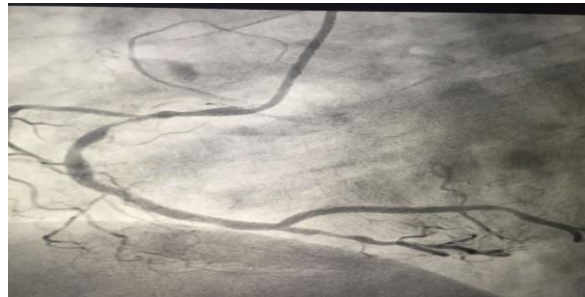


Figure 3B: stenosis in RCA

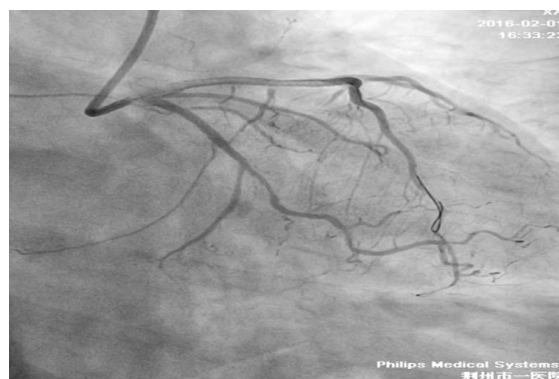


Figure 3C: During procedure

Relevant laboratory findings at 24 hours showed serum creatinine at 53.2 mmol/L, potassium at 4.5 mmol/L, troponin I at >50,000 pg/mL, LDH=532 u/L, Glucose 9.15mmol/L, CPK at 1723 u/L, and CPK-MB at 163 u/L. Initial evolution was marked by an initial hemodynamic compromise; cardiac echogram at 24 hours showed a severe systolic dysfunction (ejection fraction at 37%) with basal, mid-septal and septo-apical akinesis. The patient clinical condition improved and stabilized progressively and he was discharged on day 8; pre-discharge EKG (Fig. 4) showed a pathological Q wave from V1 to V3, along with poor progression of R wave in V4–V6, absent Q wave in V5–V6. Pre-discharge echogram showed persistent antero-septal and apical akinesis with persistent severe systolic dysfunction. Thyroid Profile was within normal range. she was advised to Follow up after one month with EKG, RFT's, LFT's, Lipid profile with following medications.

Tab. Aspirin 100mg BD

Tab. Clopidogrel 150mg OD for one month then 75 mg od then after

Tab. Atorvastatin 20mg OD.

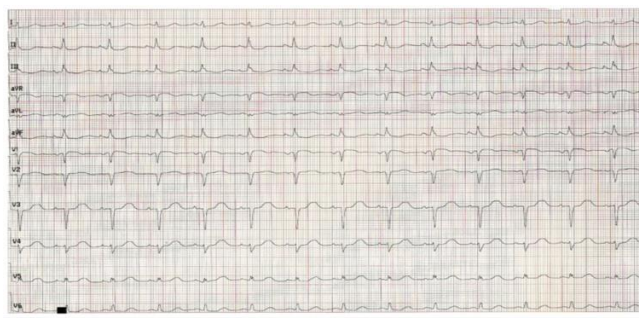


Figure 4: Electrocardiogram at discharge

DISCUSSION

Total left main thrombosis usually leads to sudden cardiac death and affected patients generally die before arriving at hospital. Conversely, patients with subtotal left main occlusion may present with acute coronary syndrome and with electrocardiographic pattern of widespread ST depression in the anterior and inferior leads.[4]in the setting of acute coronary syndromes, STE-aVR (≥ 1 mm) with diffuse ST depression in other leads is usually a sign of severe left main disease; this is often associated with a poor outcome.[2,4]Ionescu et al-[5] reported that electrocardiographic manifestations of left main coronary artery thrombosis may be nonspecific. However, STE-aVR should raise suspicions of severe left main disease and equivalent artery lesion. In addition, Taglieri et al [6] found that STE-aVR, and reciprocal ST depression in other leads in the setting of non STE acute coronary syndrome is highly predictive of severe left main disease.

Kühl et al [7] showed that STE-aVR may represent a proximal LAD artery lesion and that this

electrocardiographical sign is useful to differentiate proximal from more distal lesion in the setting of acute coronary syndrome. Along with STE-aVR, STE in V1 may be observed in anterior myocardial infarction and this finding depends on the coronary anatomy-[8] Lead V₁ reflects the right basal septal area, which is supplied by septal branches from the LAD artery alone or together with the conal branch of the right coronary artery (dual circulation). Accordingly, STE-aVR and STE in V1 predict LAD lesion proximal to the first septal branch, along with insufficient or absent flow from the conus branch. [9,10].

The mechanism of STE-aVR is not fully understood [3] Lead aVR is electrically opposite to leads V1, V2, aVL, and V3-V6, and therefore an ST depression in these leads produces reciprocal STE-aVR; [11]in addition, lead aVR directly reflects the electrical activity of the right upper portion of the heart, including the basal portion of the interventricular septum and consequently, a transmural infarction in this area theoretically produces STE-aVR. Accordingly, STE-aVR is thought to result from either one of the two following mechanisms: diffuse antero-lateral subendocardial ischemia with reciprocal change in aVR or transmural infarction of the basal portion of the heart [11] In addition, an anatomical variant of the Purkinje fibers has been evoked [3]to explain the absence of STE in anterior leads in some patients, despite transmural anterior infarction.

In this patient, we estimate that STE-aVR and V1 reflects basal antero-septal infarction (transmural) related to LAD artery sub-occlusion proximal to the first septal, along with rudimentary conus branch. Similarly, we hypothesize that ST depression in anterior and inferior leads reflects either concomitant subendocardial ischemia, and/or reciprocal changes to STE in aVR.

The clinical implication is that STE in aVR (+/-V1) coupled with ST depression in other leads suggests severe left main coronary artery or proximal LAD disease. It represents a critical clinical condition, particularly when the patient presents with hemodynamic compromise, and accordingly the condition requires prompt management. Nevertheless, the prognostic value of STE-aVR in acute coronary syndrome is still debated. Though it was found to be a strong and independent predictor of 30-day mortality in non STE myocardial infarction by Szymański et al, [12]it was not considered an independent predictor of in-hospital or 6-month mortality by GRACE investigators.[13].

CONCLUSION

STE-aVR in the setting of acute coronary syndrome is often related to severe disease of the left main coronary or proximal LAD artery and clinicians must be forewarned of this critical condition.

Acknowledgments: I would like to thank Dr. Prof, Yang Shaning for study editorial assistance.

REFERENCES

1. Kireyev D, Arkhipov MV, Zador ST, Paris JA, Boden WE. Clinical utility of aVR-The neglected electrocardiographic lead. *Ann Noninvasive Electrocardiol.* 2010;15:175–80.
2. Liang M, Kelly DJ, Devlin G. Left main stem stenosis in the unstable patient—forewarned is forearmed. *N Z Med J.* 2011;124:111–3.
3. de Winter RJ, Verouden NJ, Wellens HJ, Wilde AA. A New ECG Sign of Proximal LAD Occlusion. *N Engl J Med.* 2008;359:2071–3.
4. Fiol M, Carrillo A, Rodríguez A, Pascual M, Bethencourt A, Bayés de Luna A. Electrocardiographic changes of ST-elevation myocardial infarction in patients with complete occlusion of the left main trunk without collateral circulation: Differential diagnosis and clinical considerations. *J Electrocardiol.* 2012;45:487–90.
5. Ionescu CN, Donohue TJ. ECG findings in acute left main coronary artery thrombosis: a case report and review of the literature. *Conn Med.* 2009;73:333–5.
6. Taglieri N, Marzocchi A, Saia F, et al. Short- and long-term prognostic significance of ST-segment elevation in lead aVR in patients with non-ST-segment elevation acute coronary syndrome. *Am J Cardiol.* 2011;108:21–8.
7. Kühl JT, Berg RM. Utility of lead aVR for identifying the culprit lesion in acute myocardial infarction. *Ann Noninvasive Electrocardiol.* 2009;14:219–25.
8. Ben-Gal T, Sclarovsky S, Herz I, et al. Importance of the conal branch of the right coronary artery in patients with acute anterior wall myocardial infarction: electrocardiographic and angiographic correlation. *J Am Coll Cardiol.* 1997;29:506–11.
9. Zhong-qun Z, Wei W, Chong-quan W, Shu-yi D, Chao-rong H, Jun-feng W. Acute anterior wall myocardial infarction entailing ST-segment elevation in lead V3R, V1 or aVR: electrocardiographic and angiographic correlations. *J Electrocardiol.* 2008;41:329–34.
10. Vasudevan K, Manjunath CN, Srinivas KH, et al. Electrocardiographic localization of the occlusion site in left anterior descending coronary artery in acute anterior myocardial infarction. *Indian Heart J.* 2004;56:315–9.
11. Jong GP, Ma T, Chou P, Shyu MY, Tseng WK, Chang TC. Reciprocal changes in 12-lead electrocardiography can predict left main coronary artery lesion in patients with acute myocardial infarction. *Int Heart J.* 2006;47:13–20.
12. Szymański FM, Grabowski M, Filipiak KJ, Karpiński G, Opolski G. Admission ST-segment elevation in lead aVR as the factor improving complex risk stratification in acute coronary syndromes. *Am J Emerg Med.* 2008;26:408–12.
13. Yan AT, Yan RT, Kennelly BM, et al. GRACE Investigators. Relationship of ST elevation in lead aVR with angiographic findings and outcome in non-ST elevation acute coronary syndromes. *Am Heart J.* 2007;154:71–8.