



## **CAVERNOUS HEMANGIOMA OF THE SUPRAORBITAL NERVE: A REVIEW ARTICLE**

Dr. Sumendra Raj Pandey\*, Dr. Dipak Chuadhary, Dr. Rakesh Karn, Dr. Sohan Kumar Sah  
and Dr. Anju Ojha

*Department of nuclear medicine and medical imaging, clinical medical college of Yangtze university, Jingzhou  
central hospital, province- hubei, PR china*

### **ABSTRACT**

Cavernous hemangiomas are not true vascular tumors, but rather are slow-flow venous malformations (VMs). They are present at birth as nonproliferating vascular birthmarks composed of anomalous ectatic venous channels. VMs have often been incorrectly called cavernous hemangiomas and cavernous angiomas. These terms have for a long time lead to confusion with the more common proliferating or true hemangioma of infancy. VM has been reported to arise at all sites including skin and subcutaneous layers of the head and neck, face, extremities, liver, gastrointestinal tract, and even the thymus. Although VMs are common intraocular tumors and are involved within intracranial, extraaxial cranial nerves within the cavernous sinus has been sporadically reported, and less often in the supraorbital nerve, an extraocular and extracranial division of the trigeminal nerve has not been reported.

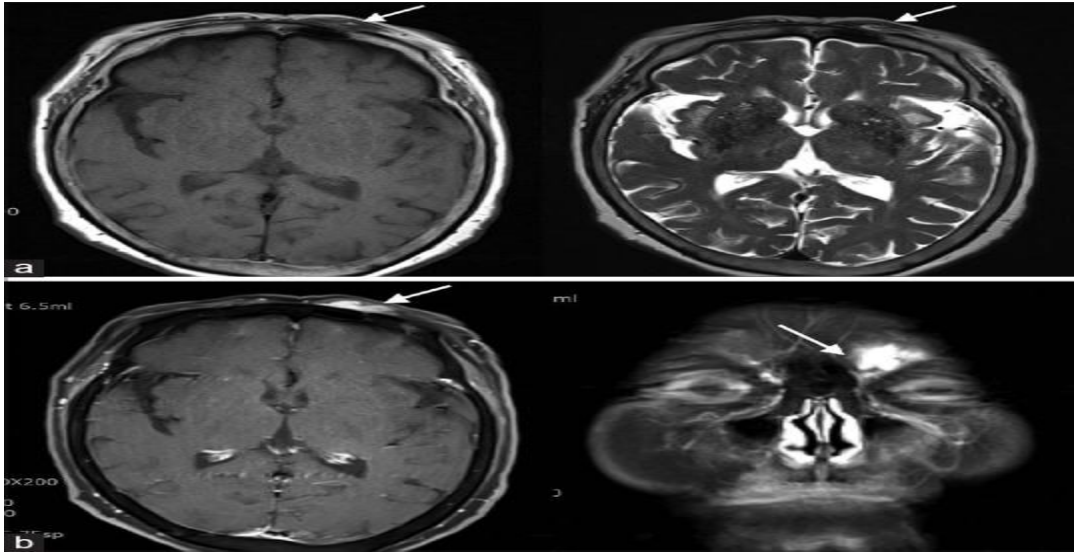
**Keywords:** *Cavernous hemangioma, supraorbital nerve, trigeminal neuropathic pain, vascular anomaly, venous malformation*

## INTRODUCTION

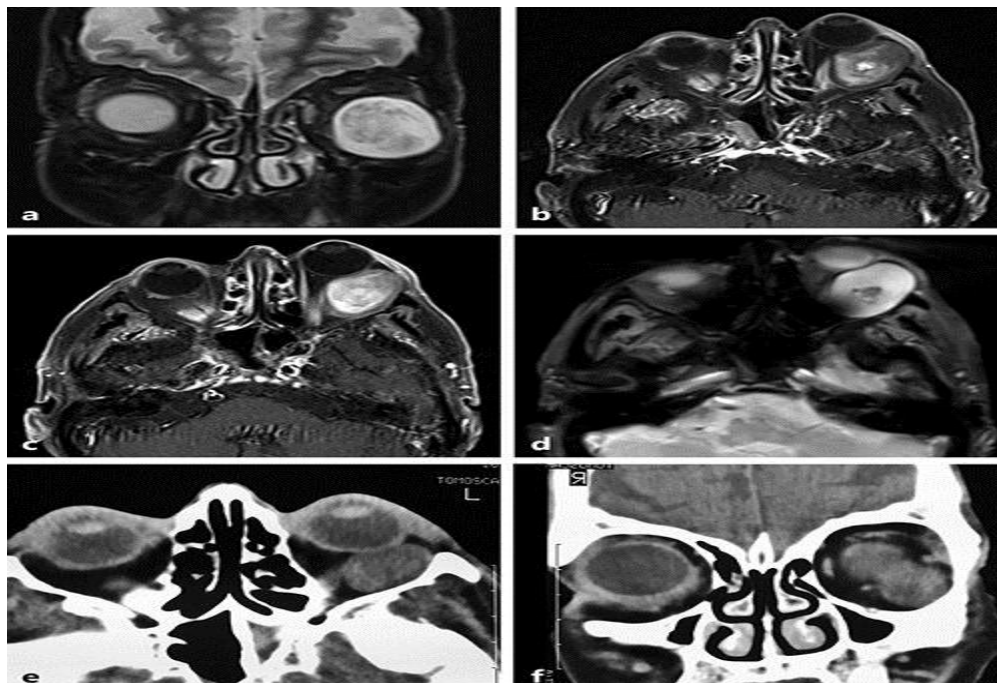
Cavernous hemangioma are the most intraorbital tumors in adults, occurring mainly in the 4<sup>th</sup> and 5<sup>th</sup> decade of life. These are well encapsulated tumors and tend to be round to oval in shape. Histologically they are composed of large, dilated, vascular channels lined by thin-attenuated endothelial cells. [1]. Cavernous hemangioma is not a vascular tumor, but rather a congenital vascular anomaly. It is classified by a venous malformation (VM) in the slow-flow lesion category by International Society for the Study of Vascular Anomalies (ISSVA)[2]. VMs are a commonly encountered entity in clinical practice, with an estimated incidence of 1–2 in 10,000 births[3] and the prevalence of 1%.[4] VMs are composed of abnormal collections of veins that have a variable luminal size and wall thickness, and geographically can appear superficial, deep, diffuse, localized, and not uncommonly multiple.[5] VMs can arise anywhere in the body and are the most common intraorbital tumors found in adults.[6] Facial VMs involve the skin and subcutaneous tissues, and oral mucosa are well-known entities. Although intracranial, intraaxial VMs (formerly called cavernous hemangiomas) and intraocular VMs are well-known to neurosurgeons, intracranial and extra-axial VMs are rare, accounting for only 0.4%–2% of all intracranial vascular malformations,[7] and tend to involve the cavernous sinus and Meckel's cave.[8]

### Imaging findings:

On CT, they appear well demarcated, smoothly marginated, homogenous, rounded, ovoid, or lobulated soft tissue masses of increased density with a variable degree of contrast enhancement owing to slow intratumoral circulation. Uncommonly phleboliths may be seen. They are normally iso-to hypointense on T1W and homogeneously hyperintense on T2W image, showing marked enhancement that becomes homogenous in delayed phase.[9]. Depending upon size of the lesions, orbital bony expansion may occur. They usually spare the orbital apex.



**Figure1:** Magnetic resonance imaging findings of the lesion. (a) T1-weighted (left) and T2-weighted axial (right) images showing a poorly-marginated, isointense signal mass (arrows) with inner high signal area possibly indicating hemorrhage or thrombosis, and dilated or serpiginous vascular structure compatible with abnormal veins. (b) T1-weighted axial (left) and coronal (right) images showing the location of lesion (arrows) with strong enhancement.



**Figure 2:** MRI showed a well-defined, oval, intraconal lesion in the left inferolateral orbit. Axial T1-weighted image shows isointensity in relation to muscle. Coronal T2-weighted image shows a heterogeneous but

mostly hyperintense signal (a). Axial post-contrast fat saturated T1-weighted images (b, c axial scans) show a progressive and heterogeneous enhancement with a more vivid central region. Axial T2 gradient-echo image (d) shows a central hypointense component suggesting the presence of micro-hemorrhages. CT scans (e axial; f coronal) revealed a large, well-demarcated, oval mass, isodense compared to the extraocular muscles in the intraconal space of the left inferolateral orbit; there was discrete bone remodeling.

## CONCLUSION

An extremely rare occurrence of VM (formerly-called cavernous hemangioma) involving the extraorbital, extracranial portion of the supraorbital nerve is discussed here in review article with its imaging findings.

## REFERENCES

1. Ruchman MC, Stefanyszyn MA, Flanagan JC, et al. Orbital tumors in Gonzalez CA, Becker MH, Flanagan JC (Eds). *Diagnostic Imaging in Ophthalmology*, New York, Springer-Verlag, 1986.
2. Mulliken JB, Glowacki J. Hemangiomas and vascular malformations in infants and children: A classification based on endothelial characteristics. *Plast Reconstr Surg*. 1982;69:412-22. [[PubMed](#)]
3. Vikkula M, Boon LM, Mulliken JB. Molecular genetics of vascular malformations. *Matrix Biol*. 2001;20:327-35. [[PubMed](#)]
4. Eifert S, Villavicencio JL, Kao TC, Taute BM, Rich NM. Prevalence of deep venous anomalies in congenital vascular malformations of venous predominance. *J Vasc Surg*. 2000;31:462-71. [[PubMed](#)]
5. North PE, Mihm MC, Jr. Histopathological diagnosis of infantile hemangiomas and vascular malformations. *Facial Plast Surg Clin North Am*. 2001;9:505-24. [[PubMed](#)]
6. Rosca TI, Pop MI, Curca M, Vladescu TG, Tihoan CS, Serban AT, et al. Vascular tumors in the orbit - Capillary and cavernous hemangiomas. *Ann Diagn Pathol*. 2006;10:13-9. [[PubMed](#)]
7. Zabramski JM, Awasthi D. Extra-axial cavernous malformations. In: Awad IA, Barrow DL, editors. *Cavernous Malformations*. Park Ridge, IL: American Association of Neurological Surgeons; 2003. pp. 133-44.
8. Biondi A, Clemenceau S, Dormont D, Deladoeuille M, Ricciardi GK, Mokhtari K, et al. Intracranial extra-axial cavernous (HEM) angiomas: Tumors or vascular malformations? *J Neuroradiol*. 2002;29:91-104.
9. Bilaniuk, L.T., Atlas, S.W., Zimmerman, R.A. The orbit: MR and CT.. in: S.H. Lee, K.C.V.G. Rao, Zimmerman R.A. (Eds.) *Cranial Computed Tomography and MRI*. ed 3. McGraw-Hill, New York; 1992:119.