



## **CEMENT AUGMENTED PEDICLE SCREW FIXATION IN SPINAL DISEASE WITH OSTEOPOROSIS: BIOMECHANICS ADVANTAGES AND COMPLICATIONS**

Bikrant Mehta\*, Ying Zhang, Jing Ming Xie, Ying Song Wang and Tian Yi Huang

*Department of Orthopedics, The 2<sup>nd</sup> Affiliated Hospital of Kunming Medical University, Kunming, China*

### **ABSTRACT**

**Objectives:** (a) Research indications designed for cement-augmented pedicle screws (CAPS) concerning patients with osteoporotic spine disease. (b) The biomechanics advantage outcome (c) The outcome complications related by this surgery technique.

**Methods:** Database were searched by using PubMed, Google scholar, Cochrane library databases were performed for articles that are randomized control trials, prospective, controlled studies and retrospective with the subsequent key words for literature searches are “Cement augmented pedicle screw fixation “Polymethylmethacrylate(PMMA)”, “Bone Mass Density (BMD)”, “Solid screw(SSs)”, “Fenestrated Screw(FSs)”, in spinal disease with osteoporosis was treated surgically using CAPS fixation included in this manuscript and reference list of preferred objects have been investigated since the database (1993-2020). Articles has been chosen reviewing biomechanics advantage and complications in osteoporotic spine disease who underwent Cement augmented pedicle screw fixation method.

**Results:** Total 387 manuscript out of which 10 articles were included in this study to assess the biomechanics outcome of cement augmentation pedicle screw to observe the pullout strength in severe osteoporosis or osteoporosis bone of different screw design fenestrated screw (FSs), or Cannulated screw and solid screw (SSs) with different volume of PMMA. were replicated using synthetic bone blocks and cadaveric human bone with different density and different pedicle screw augmented method. However total 303 article was founded from (1993-2020) about clinical complication related to this study design in which 7 prospective studies and 5 retrospective studies was included, the major complication was Cement leakage lead to pulmonary cement embolism was observed in this study. However, cement leakage complication related to CAPSF in this study were Asymptomatic.

**Conclusion:** CAPSF has been widely used in osteoporotic spine disease. However, biomechanics outcome and Cement augmented related complication CL, PCE, neural function, wound infection, were studied. This method

facilitated to increase the stability in osteoporotic vertebral patient and give improvement in clinical and radiological studies.

**Keywords:** PMMA, cement, vertebral fracture, osteoporosis, pedicle screws, complications, biomechanics advantage, Bone Mass Density (BMD)

## INTRODUCTION

### Osteoporosis:

It's a disease of old aged population that lead to decrease in bone potency and increase fracture risk due to low bone mass, worsening of bone tissue and disturbance of bone micro-architecture. It is constantly increasing whole over the world. It became a major problem health problem [1-2]. About 200 million people suffering from osteoporosis [3]. According to current data from international osteoporosis foundation it was reported that in both Europe and USA, the incidence of osteoporosis about 30% women are osteoporotic and 40% postmenopausal women and 30% men will experience an osteoporotic fracture in their whole lives [4-5]. However, in some patient surgery in not indicated because of poor bone quality. Due to increasing number of osteoporosis patient it's become big concern for spine surgeon to perform surgery [6-7].

- ❖ Spinal degenerative disease afflicts a significant portion of the elderly and is increasing in prevalence.
- ❖ Some of these individuals suffered vertebral fracture, deformity, and/or neural element compression due to osteoporosis. In some cases, surgical treatment is unavoidable.
- ❖ One of the challenges in spinal surgery is how to achieve optimal fixation of the pedicle screws and reduce loosening at the bone-screw interface in osteoporotic spinal levels. Therefore, techniques to enhance the fixation of pedicle screws are required.
- ❖ Several studies demonstrated that the fixation strength in osteoporotic bone has been increased significantly with polymethylmethacrylate (PMMA) augmentation of the pedicle screws.
- ❖ Various types of cement augmented pedicle screw fixation (CAPSF) have been described in the literature, including pre-filling PMMA with solid screws (SSs) and filling PMMA through fenestrated screws (FSs).
- ❖ Meanwhile, high rates of cement extravasations have also been noted. Leakage of cement from the vertebral body generally occurs through venous drainage of the vertebral body or through cortical defects of the bone, with lower rates of clinical significance.
- ❖ Indeed, pulmonary cement embolism (PCE) may occur and leads to disastrous consequences.

The objective of this retrospective manuscript was to assess the biomechanics outcome, incidence of complications related to Cement augmented pedicle screw fixation (CAPSF) in Spinal disease with Osteoporosis

## MATERIALS AND METHODS

### Major Queries:

- ❖ What are the Indications for Cement Augmented Pedicle Screw Fixation (CAPS)?

- ❖ What are the Biomechanics outcome of Cement augmented pedicle screw fixation?
- ❖ What are the-complication of CAPSF

**Our review article was divided in to two parts:**

- ❖ 1.The Biomechanics outcome of CAPSF.
- ❖ 2. The Complication of CAPSF

**Eligibility Criteria for Selection of Studies:**

Biomechanical studies testing of cement-augmented pedicle screws in human cadaveric or synthetic cadaveric bone included in this study, Case studies, Prospective studies, retrospective studies, clinical studies, randomized control trial, were implicated in this study. However, complication related with osteoporotic and spinal degenerative disease patient were chosen for treatment with CAPSF method included in this study.

- ❖ The indications of CAPSF surgery was investigated by researching the inclusion and exclusion criteria from year 1993 to 2020 independently according to key word, using the search terms “pedicle screw” combined with “augmentation,”. However, CAPSF method used in osteoporotic spine disease included in this study were discussed in detail.
- ❖ The journal article related with biomechanics outcomes of cement augmented screws used in human cadaveric and synthetic cadaveric bone since year 1993 were searched and evaluated.
- ❖ All the article database was searched related with CAPSF complication in cases of osteoporosis and spine disease since 1993-2020.

**Data Extraction:**

Related articles database were searched by using PubMed, Google scholar, Medline, Cochrane library databases were identified from 1993 to 2020 for articles that are randomized control trials, prospective studies, Case studies, retrospective and reviews, with the subsequent key words for literature searches are “Cement augmented pedicle screw fixation(CAPS), “Polymethylmethacrylate(PMMA)”, “Bone Mass Density (BMD)”, “Solid screw(SSs)”, “Fenestrated Screw(FSs)”, “PMMA,” in spinal disease with osteoporosis treated surgically using CAPS fixation included in this manuscript. Studies describing the Biomechanics advantages and the complication of pedicle screw in human cadaveric or synthetic cadaveric bone were included. “Kyphoplasty” and “Vertebroplasty” technique are not included in this article. However, clinical data, technique reports, case reports, review papers, letter to the editor, not in English include in this article, studies only with animal bone tissue and modeling data were excluded. To find the appropriate study, we scanned reference list by manually from identified trials and review article.

**Important Query:**

Studying citation, inclusion and exclusion criteria, osteoporotic spinal degenerative treatment, CAPSF method, biomechanics outcomes, CAPSF complications, study year.

## **Study Selection:**

### **Study choice was based on given following eligibility criteria:**

- ❖ Patient with osteoporosis and spinal degenerative disease.
- ❖ CAPSF method used for treatment.
- ❖ 3. Biomechanics outcomes
- ❖ 4. complication of CAPSF.

## **Data Collection:**

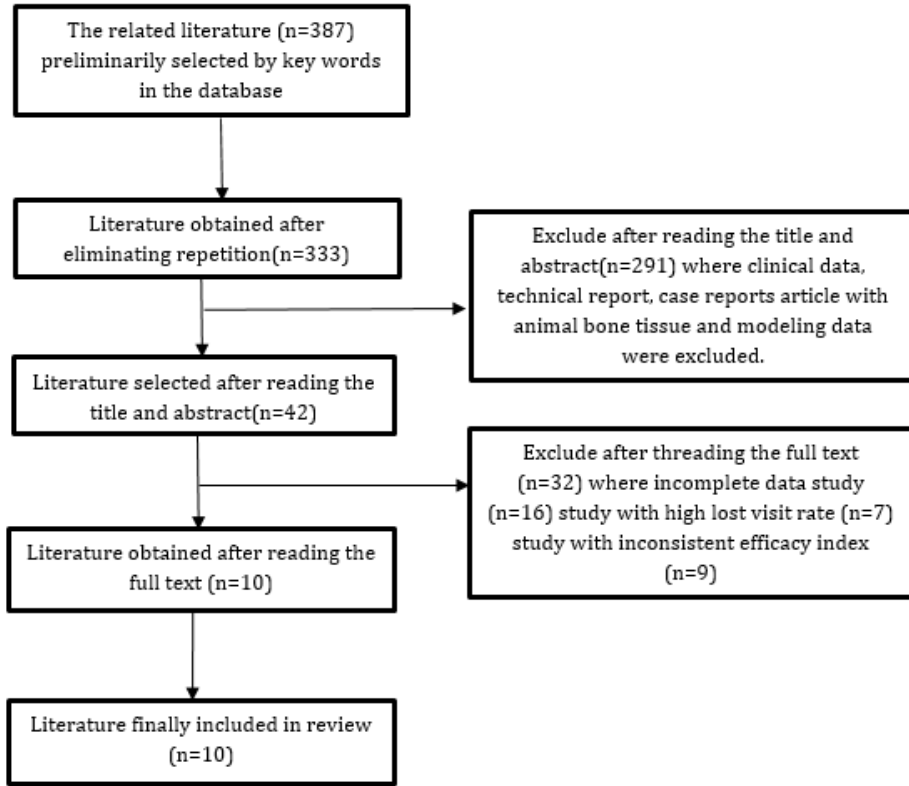
Information were collected in an arranged form which included title of the study, author details and study year, age of patients, number of patients, number of screws, indications of surgery, level of spine treated, biomechanics outcome, and complications of the surgery.

### **Part 1. Biomechanics outcomes:**

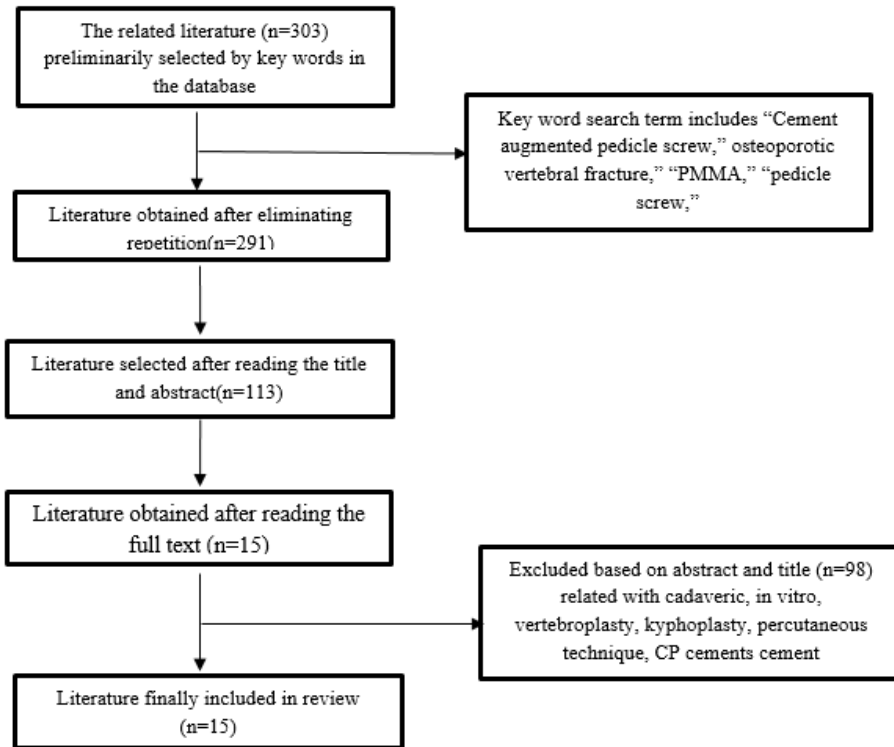
However, biomechanical testing of cement-augmented pedicle screws in human cadaveric or synthetic cadaveric bone was done with different volumes of PMMA and types of cement augmented pedicle screw to assess the axial pullout strength see flow diagram (Table-1)

### **Part 2. Complications of CAPSF:**

Cement-related complications such as infection, instrument failure, CSF leak, neurological complication. However, major complication PCE (pulmonary cement embolism), cement leakage (CL) complications were observed using C-arm fluoroscopy or CT scan postoperatively and Yeom's classification applied in numerous studies to categorize cement leak pattern based on CT scan imaging studies. (Table-2)



**Table 1:** Flow diagram study data of biomechanics outcome



**Table 2:** Flow diagram Study data of complication

## RESULTS

The preliminary related literature searched according to title and abstract was 42 articles related to CAPSF biomechanics outcome. After reviewing the full text about biomechanics outcome 10 (23%) related articles were included in this study. However, 7(16.1%) studies related to cadaveric human osteoporotic bone and 3(6.9%) studies included for synthetic cadaveric bone.

Same as clinical complication of CAPSF data was searched 35 out of 303 article using key word and term title and abstract, excluding the unrelated data and reviewing the full text article related to clinical complication 15 (42.8%) studies was included in this review. Out of 15 (42.8%) Article, 9 (25.7%) prospective study, 6 retrospective study (17.1%) included in this study.

### Indication of CAPSF:

Usually, several spine surgeons have developed various new method and instruments that expanded the indications of cement augmented pedicle screw fixation for treatment Spine disease with osteoporosis. The Spine surgeon chooses operating method according to indication of CAP (Cement Augmented pedicle) Screw fixation for management of Spine disease like osteoporotic spine, spinal degenerative disease, Scoliosis, ADS (Adult Degenerative Scoliosis), and so forth. However additional surgical indications were associated osteoporotic vertebral fractures, neurological deficit following vertebral fracture, progressive kyphosis, failure of conservative treatment leading to diminished quality of life. Patients with severe osteoporosis based on BMD were treated with CAPS in most of the studies. Most of the studies were still lack regarding indication of surgery according to demand of spine surgery.

Author/ study year	Sample model	Levels	Cement	Screw and Cement Implantati on	Cement Volume (cc)	Biomechanics	Outcomes
Sven et al. (2004)	Normal vs osteoporo tic cadaveric vertebrae	L1-L5	PMMA	Solid, with or without cement	2	Cyclic compressive loading	No difference in screw migration with cement in normal bone, less displacement with cement in osteoporotic bone
Chao et al. (2013)	Osteoporo tic cadaveric spines	T10-L5	PMMA	Fenestrated (prefilled or through screw)	2	Axial pullout, stiffness, energy to failure	4 to 5.6-fold increase in pullout strength with cement, pre-filling hole with higher failure energy than

							injecting through fenestration
Goost et al. (2014)	Normal vs osteoporotic cadaveric vertebrae	T12-L5	PMMA	Fenestrated, with or without cement	3	Axial pullout	2.1-fold increase in pullout strength for osteoporotic group, 1.5fold increase in normal group
Kueny et al. (2014)	Osteoporotic cadaveric vertebrae	L1-L5	PMMA	Fenestrated, prefilled, screw injected, large diameter nonaugmented	NR	Toggle fatigue testing, axial pullout	Both cement augmentation techniques increased pullout force, but better fatigue resistance in screw injected group
Choma et al. (2012)	Osteoporotic cadaveric vertebrae	T6-L5	PMMA	Non-augmented, solid with PMMA, partially fenestrated, fully fenestrated	2	Axial pullout, removal torque	All augmentation techniques significantly better pullout strength than control; partial fenestration had better pullout strength than solid screw with cement prefilling
Frankel et al. (2007)	Osteoporotic cadaveric vertebrae	T5-L5	PMMA	Solid, with or without cement	<2.8 vs >5.5	Axial pullout	2.2-fold increase in pullout strength with augmentation, no change with higher cement volume

Pare et al. (2011)	Osteoporotic cadaveric vertebrae	T7-L5	PMMA	Solid vs fenestrated screw with cement	0.5, 1, 1.5 (thoracic); 1.5, 2, 2.5 (lumbar)	Axial pullout, removal torque	All volumes except 0.5 cc had significant increase in pullout strength, no difference for higher volumes
Chen et al. (2011)	Synthetic bone blocks simulating severe osteoporosis	N/A	PMMA	Solid vs fenestrated, conical vs cylindrical	3	Axial pullout	Prefilling cement had improved pullout strength compared to fenestrated screw injection
Chen et al. (2009)	Synthetic bone	N/A	PMMA	Fenestrated screw, with or without radial holes	3	Axial pullout	Pullout strength increased with greater number of radial screw holes
Folsch et al. (2012)	Synthetic osteoporotic bone	N/A	PMMA	Fenestrated screw	0.5-4.5	Axial pullout	Significant increase in pullout strength from 2-3 cc, with linear correlation up to 4 cc cement

**Table1:** Details of the Biomechanics Outcome Studies.

**Abbreviations:** PMMA-Polymethylmethacrylate, NR: not recorded, N/A: not applicable.



Authors (year)	Age(years)	Sample size	Screw No.	Complication	
				Pre op	Post op
					Clinical
Chang et al. (2008) Retrospective study	75.1(range 50-90)	41	300(C291)	CL (Yeom's classification): 22 (26.2%) screws: Type S 15 (68%); type B 7 (32%)	Deep infection: 2(4.87%) Neurological improvement 31 (76%) patients (Frankel grading)
Janssen et al. (2017) Retrospective study	71+11.2(range 46-93) years)	165		CL 110 (66.7%), Radiological CL 13 (7.9%), symptomatic CL 5 (3%), Anaphylaxis, cement induced 1.2%	Superficial infection- 3(1.81%), CSF leak- 3(1.81%) case, Pulmonary cement embolism (7.9%) in 13 case
Martin-Fernandez et al. (2017) Retrospective single-center study.	73.6+7.2(range 40.4-90)	313	780	CL: 62.3% of vertebrae. asymptomatic	-deep infection 13 (4.1%), -No instrument related complication -2(0.6%) had radicular pain at S1 foramina
Pinera et al. (2011) Prospective study	Mean age 77 year	23	103	CL (Yeom's classification) 29.3% of vertebra. Type B 8 (13.8%); type S 12 (20.7%); type C 3; foraminal 2 (3.4%), 1(3.4%) extra vertebral, no nerve root symptoms.	-3 (13%) deep infections -2 screws -Mispositioning -Implant related complication- No screw loosening or back-out

Park et al. (2015) Prospective study	72(range65-85)	10	-	CL 1	Superficial/deep infection 0
Guo HZ et al. (2019) Prospective study		202	950	-	CL-16(81.68%) and 335 screws (35.26%), CL types S-255(76.12%), type B-77(22.99%), type C-30(8.96%) of screws,
Abousayed M et al. (2018) Retrospective observational study.	Mean age 24.84 months	25		CL-5	Implant related complication- no screw loosening, no screw back out
Wang Z et al. (2019) prospective study		128	418	-	Cement extravasation in 27 patients, Infection -0 Blood clot-0
Girardo M et al. (2017) Prospective study	73.4 years	52 patients (20 males and 32 females)	410	8 cases-CL (Yeom classification) CL Type C-1, Type B- 2, Type S-5, - No neurological deficit -CSF leak-0	-Thrombophlebitis-3(5.7%) -superficial infection-2(3.84%) -screw loosening-0

Mueller IU et al. (2016) Prospect ive cohort studies		98	474		-Asymptomatic perivertebral CL- 88 (93.6%) and 165 augmented vertebrae (73.3%). - PCE-4 (4. %) cases Asymptomatic.
Dai F et al. (2015) Prospect ive studies		43	125	cement leakage-4 patient	no neurological complication
Seo et al. (2012) retrospe ctive stu dy	C: 66.5 (range 49- 74); NC:62.8 (range 46- 69)	250 (C 157, NC 93)	C 947, NC 458	CL 2 (transient hypoesthesia 1, motor weakness 1)	Deep infection (C 1; NC 2), Screw loosening: C 0; NC 5 (revised with cemented screws)
Ullusoy et al. (2018) retrospe ctive study	70.5 (51- 89)	281	2978	224(79.7%) CL	-symptomatic PCE 1.4% (4 of 281) -46(16.3%) PCE radiologically
Wuisma n et al. (2000) Prospect ive studies	36.1 (range 11-62)	7	48	CL 1.92% (4/48 screws)	1. Transient nerve palsy -1 2. Pulmonary embolism- 1 3. screw loosening -0
Moon et al. (2009)	68.7 (range 57-88)	37	168	CL 2 (5.4%)	1. Superficial infection: 0 2. CSF leak, delayed 2 3. Screw loosening: 1 (2.7%)

Prospective studies					
---------------------	--	--	--	--	--

**Table 2:** Details of the Clinical Complication studies.

**Abbreviations:** CL-cement leakage, PCE-pulmonary cement embolism, CSF-cerebral spinal fluid, C-Cemented, NC-Non cemented

## Discussion

### Part 1. Biomechanics outcome of CAPSF in cadaveric human and synthetic model:

Globally used PMMA cement in osteoporosis become a tough task for spine surgeon to improve the stability of pedicle screw fixation. however due to excellent biomechanical outcome PMMA cement, it was become the first choice for spine surgeon to enhance pedicle screw fixation. Previously, PMMA cement used to directly inject in the pilot hole lots by many scholars to enhance screw stability. However due to improvement of study, scholars started to infuse PMMA cement through different-designed injectable pedicle screw to increase screw stability. Though, there was significant difference in the volumes of PMMA injected and in screw stability among different experiments. PMMA cement used to fill trabecular space provides strong fixation. It increased axial pull-out strength and decreased loosening after PMMA cement augmentation of pedicle screws [8]. Usually biomechanical property of pedicle screw fixation examined using two methods: axial pullout testing and cyclic cephalocaudal toggle displacement [9].

However, axial pull out testing become frequently used (ASTM F543) because of easy arrangement and reliable outcome. Many studies have been proven to know the importance of screw augmentation with PMMA in osteoporotic cadaveric bone and synthetics cadaver bone to assess the biomechanics properties.

### The Effect of pullout strength on Cement Volume on Pedicle Screw Augmentation:

There are several studies compared the effect of different cement volume on pullout strength. Two studies Frankel et al. [10] and Folsch et al. [11] compared studies about biomechanics outcome with different volume of augmented PMMA cement injected through Fenestrated screw in osteoporotic cadaveric vertebra and synthetic vertebral bone respectively, According to Folsch et al. [11] cement PMMA injected in to the synthetic vertebra range of cement volumes commonly used from 0.5-4.5 cc. However, up to 4 cc, volume of 2cc to 3cc cement injected in synthetic bone enhanced the axial pullout strength. Similarly, Frankel et al. [10] usage PMMA cement mean volume 3.7 (range 2–8.0 mL) through novel fenestrated screw in human cadaveric model at the level T5 and L5 vertebra to increase pedicle screw fixation. Its enhanced pullout strength in both primary and revision methods by 119% and 162% respectively, following PMMA augmentation. however, pullout strength did not significantly alter with increased cement injected between the low-cement group ( $\leq 2.8$  mL/pedicle) and the high cement group ( $\geq 5.5$  mL/pedicle). Similarly, Chen et al. [12] noticed that

injection of PMMA cement 1, 2, 3 mL substantially enhanced the biomechanical screw stability by 259%, 508%, and 715%, respectively, there were significant changes in screw stability between augmented PMMA cemented group and non-augmented group in severely osteoporotic synthetic blocks. However, fixation strength of screw increased with each 1 mL increased of PMMA cement. So that difference in volume of PMMA result in biomechanical difference of screw stability was observed in many studies. The reviewed studies indicated that a volume around 2-3 cc maximized the initial fixation of the screws.

### **The Effect of Axial pullout strength on Pedicle Screw Augmentation through Fenestrated or cannulated pedicle screw (FPSs) and solid screw (SSs):**

Pare et al. [13] compared pullout strength between augmented and non-augmented vertebra injected with different volumes of PMMA into vertebrae through fenestrated pedicle screws (0.5, 1.0, and 1.5 mL in thoracic vertebrae, and 1.5, 2.0, and 2.5 mL in lumbar vertebrae). Except for the screw receiving 0.5 mL of PMMA augmented through fenestrated screw in thoracic vertebrae, the augmented fenestrated screws as compared with non-cement-augmented pedicle screws for the screws receiving 1.0 mL (186%) and 1.5 mL of PMMA (158%) in the thoracic vertebrae respectively, so that pullout strength significantly increased in augmented fenestrated screw. However, the cement PMMA injected through screws with volume of 1.5 mL (264%), 2.0 mL (221%), and 2.5 mL (198%) in the lumbar vertebrae was Statistically significant increase was noticed in this study. There was no significant difference was observed at higher volumes of cement used to increase the screw stability. However, author did not evaluate the correlation between screw stability and volume of PMMA cement in their research. However, several comparative researches were focused on fenestrated augmented pedicle screw of different volumes of PMMA cement injection, only some researches centered on the traditional injection technique. As we realized, it was tough to get osteoporotic and severe osteoporotic cadaveric spinal model. In this study, Chen et al. [14] studied in synthetic bone was applied as alternative for cadaveric spinal bone because of reliable and similar structural properties. Nevertheless, of the screw external geometry (conical or cylindrical), solid screws with retrograde cement pre-filling showed significantly higher pullout strength than cannulated screw with retrograde cement pre-filling, however, solid screws without cement augmentation showed the lowest pullout strength. For the conical screws, the solid type provided a 23% increase in the pullout strength when compared to the cannulated type. As compare to cylindrical screws, the solid type provided a 41% increase in the pullout strength when matched to the cannulated type. For a given screw augmentation method (screw without cement augmentation, cannulated screw with cement injection or solid screw with cement pre-filling), there was no significant variation in axial pullout strength was observed among conical and cylindrical screws. Similarly, Ying et al. [15] measured the pullout strength of PMMA augmentation of fenestrated screws in synthetic osteoporotic bone after augmentation and screwing out, three threads 24 hour later. They observed that all augmented screws had a significant increase in pullout strength compared to non-augmented screws, however, altered screws had lower pullout strengths than the non-altered screws. Moreover, after screwing in three threads, a radiolucent cavity was noted in the vertebral body due to migration of the cement-screw complex. Chao et al. [16]

determined the biomechanical property, cement injected through fenestrated screws with either cement pre-filling or injection through the screw the pull-out strength and stiffness-to-failure ratio of cement pre-filled and cement-injected screws were significantly higher than the non-cement-augmented control group. However, the cement pre-filled and cement-injected groups did not differ significantly, even though comparison between placing fenestrated screws in pre-filled cement and injecting through the screw, both techniques improved axial pullout force but there was better fatigue resistance in the screw injection group.

Though, many researches compared pullout strength between solid and fenestrated screws. Due to varied biological outcomes between cement pre-filling, cement augmented through fenestrated screw recommend that at best. however, cement augmented fenestrated screw technically easier, numerous extra complications are introduced with their use. There are many types of screw designs for cement augmentation that effect the biomechanical outcome, by alterations in fenestration position, size and the number of fenestrations. Moreover, the viscosity of the cement may be more significant with fenestrated screws due to smaller holes to inject through, with possibly much larger injection pressures required. Choma et al. [17] compared the effects of PMMA augmentation in osteoporotic vertebra from T6-L5 and found no difference in axial pullout strength between high and low viscosity cement. Furthermore, there was some conflict with the location of the cement, as it primarily concentrated outside of the proximal fenestration, while more diffuse cement along the screw tract has been shown to lead to improved screw fixation [18].

In this review study about biomechanics outcome of Cement augmented pedicle screw fixation not only founded the relationship between screw stability and volume of PMMA and the preferred volume of injected PMMA in synthetic bone blocks and cadaveric human model with different density, but also provided the feasibility for the future study in vertebral samples. The result in this study also provided the guideline for the injected volume of cement and different method used for screw fixation in osteoporotic spine disease in vertebral body in the future.

As we knew, there were different microstructures of bone tissue in different vertebral bodies. There were also different microstructures of cancellous bone in different regions in one vertebral body. For this reason, we cannot ensure the exact same distribution and interdigitation of PMMA augmented screw fixation to the surrounding bone tissue by vertebra to vertebra. That may bring influence on the fixation strength of pedicle screw. In order to study relationship between the different distribution of PMMA and fixation strength, we also had designed several injection sheaths with different lateral holes. With the same volume of injected PMMA, we found varying distribution of PMMA augmented method and varying screw stability. The results of that experiment are still being interpreted and still concern for future study. (Table 1.)

## **Part 2. The complication of CAPSF:**

Complications associated with PMMA augmented cement were observed in this study. However, CAPSF method was used in this study to enhance the pedicle screws stability in poor quality bone. Most common complication observed in the studies was Cement leakage (CL), however, complications of Cement Leakage lead to pulmonary embolism (PCE) also noticed in few studies. Less complication such as infection,

nerve injury, Cerebral spinal fluid (CSF) leakage, instrument related complication Screw loosening, Screw migration, including terms cut-out, pull-out, cut-through, back-out, Screw breakage was also included. However, total number of patient 1547 and 8159 screw was including in our studies. (Table.2)

**Cement Leakage (CL):** The more common complication CL (cement leakage) that lead pulmonary cement embolism (PCE). The leakage pattern classified according to Yeom's [19] classification was Type-B leakage - basivertebral epidural veins, type-S- segmental veins, and type-C- cortical defects. Janssen et al. [20] mentioned in their retrospective studies out of 110 of 165 sample of patients in which Cement leakage (66.7%) was observed clinically asymptomatic. Similarly, Martin-Fernandez et al. [21] in their retrospectives studied 313 sample patients and 780 screw was included in their studies, Cement leakage was observed in 650 vertebrae (62.3%). No severe clinical complications related to CL. Comparing the both clinical studied its suggested that Jansen et al. [20] has high (7.9%) incidence of CL as compared to Martin-Fernandez et al. [21] in their retrospectives studied. Similarly, Ullusoy et al. [22] in retrospective series, used 2978 cement augmented fenestrated pedicle screw (CAFPS) in 281 patients, 224 (79.7%) patients had bone cement leakage. The analysis of the leakage causes may be related to the amount of cement injected into each pedicle screw. However, the risk of CL is higher in various spinal instrumentation surgery.

**Neurological complication:** Four studies were included to observe neurological complication one comparative retrospective studies was done by Seo et al. [23] in 2012 using 146 out of 157 patients (93%) in Group A and 83 out of 93 patients (90%) in Group B, none of the patients experienced serious complications. However, 2(1.8%) patient had neurological complication, 1 patient transient hypoesthesia, 1 had motor weakness due to bone cement extravasation in group A. Similarly, prospective study was done by Girardo M et al. [24] no any neurological deficit was observed. However according to Chang et al. [25] in Retrospective study neurological improvement 31 (76%) patients according to Frankel grading). Martin-Fernandez et al. [21] had observed 2(0.6%) had radicular pain at S1 foramina. As comparing three studies total (2.4%) neurological complication observed in Seo et al. [23] and Martin-Fernandez et al. [21] however there was neurological improvement 31 (76%) study done by Chang et al [25]. Wuisman et al. [26] observed in 1 patient had transient nerve palsy out of 4 patients.

**Infection:** The clinical complication after CAPSF method was used in osteoporotic spine infection like superficial infection and deep infection complication was observed in this study include 3 retrospective, 2 prospective study and one comparative study. Janssen et al. [20] observed 3(1.81%) Superficial infection. Similarly, Martin-Fernandez et al. [21] in their retrospectives studied 13 patients (4.1%) had got deep infections, 2 had chronic infections. All patients responded well to antibiotic therapy. Chang MC et al. [25] founded 2(4.87%) patient had deep infection in their retrospective study. Seo et al. [23] in retrospective study was done to compare the cement augmented and non-cement augmented screw fixation deep infection complication was observed, cement augmented group and non-cement group 1(0.63%) and 2 (2.1%) respectively. In two prospective study done by Girardo M et al. [24] and Piñera AR et al. [27] they observed 3 (5.7%) thrombophlebitis, 2 (3.84 %) superficial infection and 3 (13%) deep infections respectively.

**Implant Related Complication:** Instrument related complication Screw loosening, Screw migration, including terms (cut-out, pull-out, cut-through, back-out, Screw breakage). In this study implant related complication was included in four studies two retrospective studies and two prospective study. Piñera AR et al. [27] in their prospective study using cannulated cemented pedicle screw instrumentation in the elderly patient mean age 77-year, 23 patients were included, 103 screw, 58 cemented vertebrae in 23 patients was injected using PMMA augmented cannulated screw 2 cases has foraminal leakage due to screw malposition and 1 extra vertebral; 2 screws -Mispositioning, no Implant related complication- no screw loosening or back-out has been observed. Similarly, Girardo M et al. [24] in their prospective studies between 2011 to 2015 treated 52 patients (20 males and 32 females) age range between 65 and 82 years, 410 fenestrated PMMA augmented pedicle screw. No cases of screw loosening were recorded.

However, Moon et al. [28] in Prospective studies from 2005 and 2007 in Thirty-seven patients with degenerative spinal stenosis and osteoporosis underwent lumbar fusion the implant related complication Screw loosening was observed in 1 (2.7%). Seo et al. [23] observed no Screw loosening in Cement augmented screw, however 5 cases had screw loosening was seen in non-cemented screw that required re-operation for bone cement augmentation.

#### **Cerebral Spinal fluid (CSF) leakage:**

Two studies were done related to complication of CSF in this review Moon et al. [28] and Jansen et al. [20] had observed 2 delayed cases CSF leak and CSF leak was seen in 3 (1.84%) patients respectively. Similarly, Girardo M et al. [24] in their prospective studies no CSF leak was founded.

#### **(Pulmonary Cement embolism) PCE:**

Janssen et al. [20] PCE was observed in 13 patients (7.9%) in which five patients (3.0%) were presented with symptom. total (5.5%) in nine patient symptomatic complication was observed. similarly, Ullusoy et al. [22] in retrospective series total 46 (16.3%) patients had pulmonary embolism radiologically observed. However only 4 (1.4%) (4 of 281) patient had the incidence of symptomatic PCE was seen. Wuisman et al. [26] and Muller et al. [29] observed PCE complication in their study 1 case of PCE and 4 (4. %) PCE cases asymptomatic respectively.

Overall pulmonary cement embolism (PCE) was reported in 16 cases (1.5%); highest incidence of PCE 7.9% was described by Janssen et al. [20] in their study. PMMA cement injected through cannulated pedicle screw was effective for osteoporotic patients who underwent spinal instrumentation and decompression surgery. CL related PCE complication more observed in this study however the majority of CL cases were asymptomatic, CL was classified according to Yeom's classification.[19] Type-B (leakage occurred through basivertebral epidural veins), type-S occurred through (segmental veins), and type-C through (Cortical defects).

Four studies were used Yeom's classification to define cement leak in this study. Most common pattern of CL occurred through basivertebral veins (type S, Segmental veins). Similarly, Guo HZ et al. [30] in their retrospective studies cement leakage types of S, B and C were seen in 255 (76.12%), 77 (22.99%), and 30



(8.96%) of screws, respectively. Piñera AR et al. [27] in their prospective study Cement leakage was observed in 29% of vertebra, Type B leakage in 8 (13.8%); type S leakage in 12 (20.7%); type C 3. Similarly, Girardo M et al. [24] in their prospective studies incidence cement leakage was seen in 8 patients, leakage pattern was recorded according to Yeom's classification. Type B -2, type S -5, type C- 1 with no neurological loss. Chang MC et al. [25] did retrospective study CL was observed according to (Yeom's classification): 22 (26.2%) screws: Type S 15 (68%); type B 7 (32%).

Abousayed M et al. [31] observed in their studies through fenestrated pedicle screw augmentation in osteoporotic vertebra cement leakage was observed in 5 cases. That's why CAPSF method through fenestrated augmented screws provided effective and lasting purchase in patients with osteoporosis and reduce the risk cement leakage.

Janssen et al. [20], Marti'n-Ferna'ndez et al. [21] and Ullusoy et al. [22] in their retrospective studies, had described incidence rates of CL 66.7%, 62.3% and 79.7% respectively, but Ullusoy et al. [22] studies show high incidence 79.7% CL in comparison to other studies. Even though, incidence of CL was asymptomatic so that no need of further treatment, so that morbidity and mortality related to cement injection has been important. Janssen et al. [20] observed 1.8% mortality rate in 30 days follow up after operation, they recommended to use proper cement augmentation. Mueller et al. [29] in their prospective cohort studies asymptomatic perivertebral cement leakage was seen in 88 patients (93.6%), 165 augmented vertebrae (73.3%). Cement leakage commonly occurred in perivertebral venous system. However, proper method of Cement augmentation technique has not reduced the incidence rates of Cement leakage related complication. Different plan has been made to reduce the risk of cement leakage. Cement augmented with Fenestrated screws become excellent choice for pedicle screw fixation in osteoporotic vertebra. two studies included Girardo M et al. [24] et al and Abousayed M et al. [31] PPMA cement injected through fenestrated pedicle screw the incidence of CL rate was 2 to 5% respectively observed less than other studies. However, no implant related complication, no CSF leakage and no neurological deficit was seen in both studies.

According to proper indication used for surgery in different spine deformity patient. Nevertheless, it was out of the current study based on the article research. Complication for CAPSF have been defined in this study in (Table.2). The incidence of complications associated with cement augmented pedicle screw cannot be ignored. However, careful use of cement injected through screw during procedure can minimize risk of vascular complications along with CL related Pulmonary cement embolism (PCE) in osteoporotic patient.

## CONCLUSION

Cement augmented pedicle screw method perhaps useful in osteoporotic spine, PMMA cement used to increase stability of pedicle screw in both cadaveric osteoporotic vertebra and synthetic bone block using CAPSF technique. There were strong correlations between screw stability and the volume of PMMA, and the screw stability was increased with the increment in the volume of PMMA. CL was the most common complication reported. Most of the CL remained asymptomatic. So, improper use of cement augmentation was

prohibited. However, risks of CL resulting from diminished bone quality but there were no any proper studies has shown than proper technique during cement augmented pedicle screw fixation minimize the risk of complication.

## REFERENCES

1. NIH consensus development Panel on Osteoporosis prevention, Diagnosis and Therapy. Osteoporosis prevention, diagnosis and therapy. JAMA. 2001; 285:785-95. [PubMed] [Google Scholar]
2. Cosman F, de Beur SJ, LeBoffMS, Lewiecki EM, Tanner B, Randall S, et al. Clinician's guide to prevention and treatment of osteoporosis. Osteoporos Int. 2014; 25:2359-81.
3. Cooper C, Campion G, Melton LJ, 3rd Hip fractures in the elderly: a world-wide projection. Osteoporos Int. 1992; 2:285-9. <https://doi.org/10.1007/BF01623184>. [PubMed] [Google Scholar]
4. Reginster JY, Burlet N. Osteoporosis: a still increasing prevalence. Bone. 2006;38(Suppl 1): S4-9. <https://doi.org/10.1016/j.bone.2005.11.024>. [PubMed] [Google Scholar]
5. Wright NC, Looker AC, Saag KG, Curtis JR, Delzell ES, Randall S, et al. The recent prevalence of osteoporosis and low bone mass in the United States based on bone mineral density at the femoral neck or lumbar spine. J Bone Miner Res. 2014; 29:2520-6. <https://doi.org/10.1002/jbmr.2269>. [PMC free article] [PubMed] [Google Scholar]
6. Halvorson TL, Kelly LA, Thomas KA et al (1994) Effects of bone mineral density on pedicle screw fixation. Spine 19:2415-2420
7. McLain RF, McKinley TO, Yerby SA et al (1997) The effect of bone quality on pedicle screw loading in axial instability: a synthetic model. Spine 22:1454-1460
8. McLachlin SD, Al Saleh K, Gurr KR, Bailey SI, Bailey CS, Dunning CE. Comparative assessment of sacral screw loosening augmented with PMMA versus a calcium triglyceride bone cement. Spine (Phila Pa 1976). 2011;36(11): E699-704.
9. Moore DC, Maitra RS, Farzo LA, et al. Restoration of pedicle screw fixation with an in situ setting calcium phosphate cement. Spine.1997;22:1696-1705.
10. B. M. Frankel, S. D'Agostino, and C. Wang, "A biomechanical cadaveric analysis of polymethylmethacrylate-augmented pedicle screw fixation," *Journal of Neurosurgery: Spine*, vol. 7, no. 1, pp. 47-53, 2007.
11. Fölsch, C., Goost, H., Figiel, J., Paletta, J. J., Schultz, W., & Lakemeier, S. (2012). Correlation of pull-out strength of cement-augmented pedicle screws with CT-volumetric measurement of cement, *Biomedical Engineering / Biomedizinische Technik*, 57(6), 473-480.
12. Y.-L. Chen, W.-C. Chen, C.-W. Chou et al., "Biomechanical study of expandable pedicle screw fixation in severe osteoporotic bone comparing with conventional and cement-augmented pedicle screws," *Medical Engineering and Physics*, vol. 36, no. 11, pp. 1416-1420, 2014.
13. P. E. Paré, J. L. Chappuis, R. Rampersaud et al., "Biomechanical evaluation of a novel fenestrated pedicle screw augmented with bone cement in osteoporotic spines," *Spine*, vol. 36, no. 18, pp. E1210-E1214, 2011.

14. L.-H. Chen, C.-L. Tai, D.-M. Lee et al., "Pullout strength of pedicle screws with cement augmentation in severe osteoporosis: a comparative study between cannulated screws with cement injection and solid screws with cement pre-filling," *BMC Musculoskeletal Disorders*, vol. 12, article 33, 2011.
15. Ying SH, Kao HC, Chang MC, Yu WK, Wang ST, Liu CL. Fixation strength of PMMA-augmented pedicle screws after depth adjustment in a synthetic bone model of osteoporosis. *Orthopedics*. 2012;35(10): e1511-6.
16. Chao KH, Lai YS, Chen WC, et al. Biomechanical analysis of different types of pedicle screw augmentation: a cadaveric and synthetic bone sample study of instrumented vertebral specimens. *Medical engineering & physics*. 2013;35(10):1506-12.
17. Choma TJ, Pfeiffer FM, Swope RW, Hirner JP. Pedicle screw design and cement augmentation in osteoporotic vertebrae: effects of fenestrations and cement viscosity on fixation and extraction. *Spine*. 2012;37(26): E1628-32.
18. Renner SM, Lim TH, Kim WJ, Katolik L, An HS, Andersson GB. Augmentation of pedicle screw fixation strength using an injectable calcium phosphate cement as a function of injection timing and method. *Spine*. 2004;29(11): E212-6.
19. Yeom JS, Kim WJ, Choy WS, Lee CK, Chang BS, Kang JW. Leakage of cement in percutaneous transpedicular vertebroplasty for painful osteoporotic compression fractures. *J Bone Joint Surg Br*. 2003; 85:83-89.
20. Janssen I, Ryang Y-M, Gempt J, et al. Risk of cement leakage and pulmonary embolism by bone cement-augmented pedicle screw fixation of the thoracolumbar spine. *Spine J*. 2017;17: 837-844.
21. Marti´n-Ferna´ndez M, lo´pez-Herrado´n A, Pin ´era AR, et al. Potential risks of using cement-augmented screws for spinal fusion in patients with low bone quality. *Spine J*. 2017;17: 1192-1199.
22. Ulusoy OL, Kahraman S, Karalok I, et al. Pulmonary cement embolism following cement-augmented fenestrated pedicle screw fixation in adult spinal deformity patients with severe osteoporosis (analysis of 2978 fenestrated screws). *Eur Spine J*. 2018;27(9):2348-2356. doi:10.1007/s00586-018-5593-1
23. Seo JH, Ju CI, Kim SW, Kim JK, Shin H. Clinical efficacy of bone cement augmented screw fixation for the severe osteoporotic spine. *Korean J Spine*. 2012; 9:79-84.
24. Girardo M, Cinnella P, Gargiulo G, Viglierchio P, Rava A, Aleotti S. Surgical treatment of osteoporotic thoraco-lumbar compressive fractures: the use of pedicle screw with augmentation PMMA. *Eur Spine J*. 2017;26(suppl 4):546-551. doi:10.1007/s00586017-5037-3
25. Chang MC, Liu CL, Chen TH. Polymethylmethacrylate augmentation of pedicle screw for osteoporotic spinal surgery: a novel technique. *Spine (Phila Pa 1976)*. 2008;33: E317-E324.
26. Wuisman PI, Van Dijk M, Staal H, Van Royen BJ. Augmentation of (pedicle) screws with calcium apatite cement in patients with severe progressive osteoporotic spinal deformities: an innovative technique. *Eur Spine J*. 2000; 9:528-533.
27. Piñera AR, Duran C, Lopez B, Saez I, Correia E, Alvarez L. Instrumented lumbar arthrodesis in elderly patients: prospective study using cannulated cemented pedicle screw instrumentation. *Eur Spine J*. 2011;20 Suppl 3(Suppl 3):408-414. doi:10.1007/s00586-011-1907-2

28. Moon BJ, Cho BY, Choi EY, Zhang HY. Polymethylmethacrylate augmented screw fixation for stabilization of the osteoporotic spine: a three-year follow-up of 37 patients. *J Korean Neurosurg Soc.* 2009; 46:305-311.
29. Mueller JU, Baldauf J, Marx S, Kirsch M, Schroeder HW, Pillich DT. Cement leakage in pedicle screw augmentation: a prospective analysis of 98 patients and 474 augmented pedicle screws. *J Neurosurg Spine.* 2016;25(1):103–109. doi:10.3171/2015.10.SPINE15511
30. Guo HZ, Tang YC, Guo DQ, et al. The cement leakage in cement-augmented pedicle screw instrumentation in degenerative lumbosacral diseases: a retrospective analysis of 202 cases and 950 augmented pedicle screws. *Eur Spine J.* 2019;28(7):1661–1669. doi:10.1007/s00586-019-05985-4
31. Abousayed M, Boktor JG, Sultan AM, Koptan W, El-Miligui Y. Augmentation of fenestrated pedicle screws with cement in patients with osteoporotic spine. *J Craniovertebr Junction Spine.* 2018;9(1):20-25. doi: 10.4103/jcvjs.JCVJS\_14\_18.