



## DUODENAL GASTROINTESTINAL STROMAL TUMOR MIMICKING A PANCREATIC HEAD TUMOR: A CASE REPORT

Dr. Mahesh Gurung\* and Prof. Dr. Huang Jinbai

*Department of Radiology, Clinical College of Yangtze University, The first affiliated Hospital to Yangtze University, Jingzhou Province, P.R. China.*

### ABSTRACT

We report a case of a 62 years male patient with the history of vomiting just after eating, lethargic, loss of appetite and weight loss for 20 days. CT scan of abdomen and pelvis, indicated a soft tissue mass with slight heterogeneous enhancement at the region of the uncinata process of the head of pancreas and MPR on CT enhanced showed the mass attached to the head of the pancreas closely. On operative exploration, the mass was found to be originated from duodenum. Then, surgical resection of the duodenal tumor by wedge resection was performed successfully and postoperative laboratory diagnosis was low risk duodenal gastrointestinal stromal tumor.

**Key words:** Gastrointestinal stromal tumor; Mesenchymal tumor; Ampulla of Vater; Imatinib; Pancreatoduodenectomy;

## INTRODUCTION

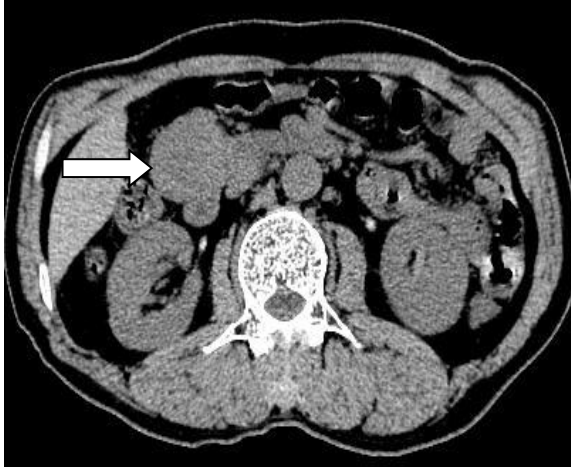
Gastrointestinal stromal tumors (GISTs) are the majority of mesenchymal tumors of the gastrointestinal tract which occur predominantly in middle-aged and older people, with an average age of 50–60 years [1] and rarely in children. The stomach is the most common location of GIST (60–70%) [2], followed by other uncommon sites like small bowel (25%), rectum (2%), and the esophagus (2%), with other various locations accounting for the rest of the presentations. Small intestinal GIST can occur anywhere along the length of the bowel and can be multiple. The duodenum is involved in about 10% to 20% of small intestinal GIST. Some GISTs are primary in the omentum, mesentery or retroperitoneum, but most GISTs in these sites are the results of metastases from gastric or intestinal sites [3-5]. Although duodenal GIST is similar pathologically to that involving other organs, they do have some peculiar features. GISTs in the duodenum pose particular challenges for diagnosis and management. Pinpoint analysis is of great concern in imaging diagnosis of duodenal GIST.

We present a case we encountered at our hospital of duodenal GIST mimicking pancreatic head tumor in a 62 years male patient which was confirmed following surgical exploration. The imaging findings, clinical course, and treatment options are reviewed.

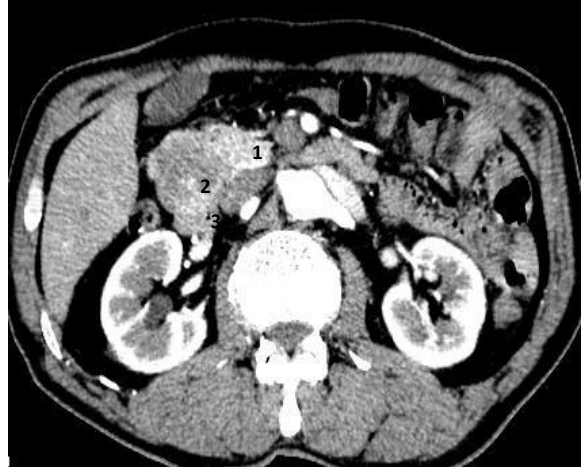
## CASE REPORT

A 62 years male patient presented in our hospital with the history of vomiting just after eating, lethargy and loss of appetite since 20 days. He also mentioned about gradual loss of weight for past few months. He didn't give any history of abdominal pain, diarrhea or constipation. Contents of vomit was non-greasy, undigested food particles. He gave the history of improvement of the symptoms while on semi liquid diet. On past history of the patient, he had bronchiectasis, denied about hepatitis, tuberculosis, and any other infectious diseases. He didn't give any history of diabetes mellitus, hypertension, drugs or food allergy. He didn't have any history of surgical intervention and denied about the history of blood transfusion. Immunization history was unknown.

On physical examination, his temperature was recorded to be 36.5°C, pulse-76 b/m, respiratory rate-19 br/m and BP-150/100 mm of Hg. His body development looked normal, had normal nutritional status, moderate sized face, independent decubital status and patient was co-operative. He was found to be non-icteric, non-anaemic, non-cynotic, no spider nevus, no any lymph node enlargement and bilateral thyroid gland were intact. The bilateral breathe sound was clear and heart rate, rhythm was regular with no any pathological murmur. The abdominal wall was soft, non-tender, no rebound tenderness and abdominal mass was not palpable. Bilateral upper and lower limb movement was intact and there was no any swelling present. Physiological reflex existed and pathological reflex was non-elicited.

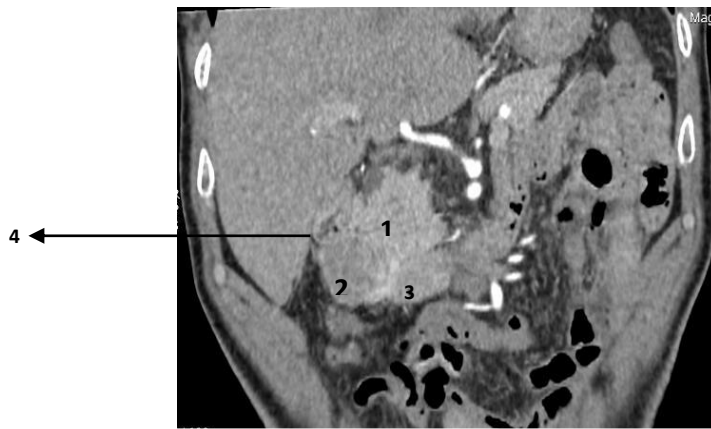


**Figure 1:** Axial plain CT showing homogeneous, eqidensity, soft tissue tumor mass in the uncinus process of the head of

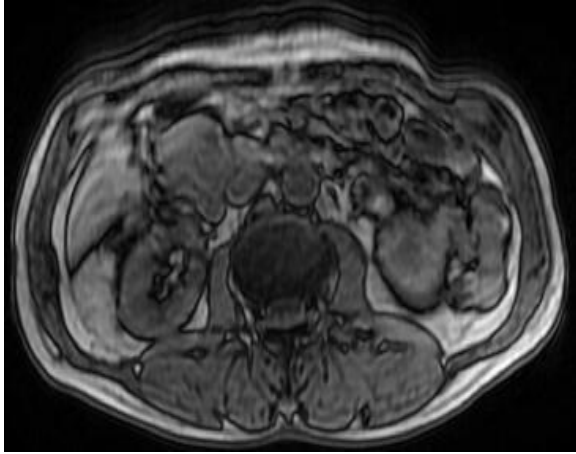


**Figure 2:** Axial enhanced CT exhibits soft tissue tumour mass showing slight heterogeneous enhancement. (1-pancreatic head. 2-tumor mass. 3-duodenum)

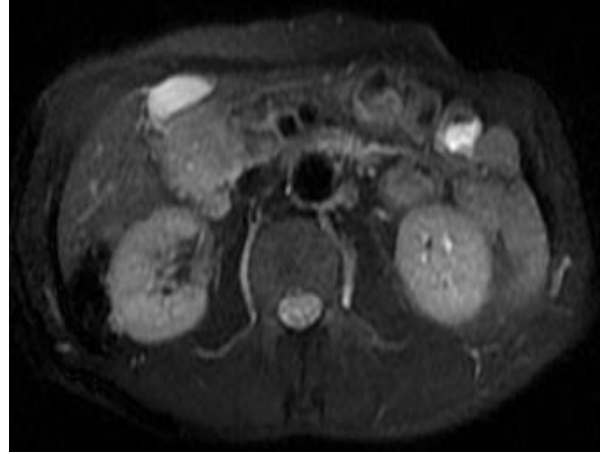On CT scan of the abdomen and pelvis he was found to have homogeneous, eqidensity, soft tissue tumor mass at the uncinus process of the head of pancreas (Fig.1). But, the site of the orgin of the tumor mass was not clear. Enhanced CT revealed slightly heterogeneous enhancement of the tumor mass (Fig.2) and the Coronal CT enhanced MPR demonstrated exophytic growth of the tumor mass at the uncinus process of the head of the pancreas showing slightly heterogenous enhancement but couldn't clarify the exact location (Fig.3). It also showed no dilation or invasion of the common bile duct and no invasion of surrounding lymph nodes. On MR studies, the tumor mass showed low signal intensity in T1 weighted image (Fig.4) and high signal intensity in T2 weighted image (Fig.5) at the head of pancreas.



**Figure 3:** Coronal CT enhanced MPR exhibits soft tissue tumor mass showing slightly heterogeneous enhancement at the uncinus process of head of pancreas. (1- Head of pancreas, 2- tumor mass, 3- 2<sup>nd</sup> part of duodenum, 4- colon)



**Figure 4:** Axial T1-weighted image demonstrating soft tissue mass of slightly low signal intensity at the head of pancreas.



**Figure 5:** Axial T2-weighted image demonstrating soft tissue mass of slightly high signal intensity at the head of of pancreas.

On the basis of these findings, the tumor of the head of the pancreas was strongly suspected and surgical management was planned. Then the patient underwent surgery in our hospital during which the tumor was found to be located in the lower part of duodenum and horizontally inside, pushing the head of pancreas inward. The tumor had not extended into the uncinate process and the root of the superior mesenteric vessels. The size of the tumor was about 3.5cm\*4cm, soft, lobulated and rich in superficial blood vessels. The duodenum was depressed and the tumor was attached to the wall of the duodenum compressing the head of the pancreas. There was no obvious invasion of the surrounding structures seen. The mesenteric vessels, portal vein and surrounding lymph nodes were devoid of invasion and a separation between the tumor and the pancreas could be clearly seen but a white bulge like lesion was seen on the wall of gallbladder. So, resection of the tumor by wedge resection with cholecystectomy was performed successfully.

The histological assessment was suggestive of Low risk duodenal gastrointestinal tumor, size of tumor was 4cm\*4cm\*3cm, and mitotic activity was <5/50HPF. Immunohistochemistry showed CD34 (+), CD117 (+), Dog-1 (+), S-100 (-) Ki67Li about 3%. The patient is under regular follow up and has shown no sign of disease.

## DISCUSSION

GISTs are the most common form of tumors of the gastrointestinal tract. These tumors arise from the interstitial cells of Cajal, which are located in the submucosal and myentric plexus and ranges from 0.1-3% of all gastrointestinal tumors. The diagnosis of GIST is done by immunohistochemistry and electron microscopy where the presence of staining for tyrosine kinase receptor KIT (CD 117) is confirmatory for the presence of

the interstitial cells of Cajal. On estimation of over 95% of GISTs shows positive staining results for CD 117 in the diagnosis of GIST [6]. It also shows positive results for nestin (90–100%) and CD34 (70%) but they are less specific in comparison to CD 117. Smooth muscle actin(SMA) (20– 30%) and heavy caldesmon (80%) are often expressed, whereas desmin is usually absent. Histologically, the structures of GISTs vary from cellular spindle cell tumors to epithelioid and pleomorphic ones, and morphology varies depending on the lesion sites. The expression of CD34 and SMA is often reciprocal. These immunohistochemical assays help in distinguishing GISTs from other gastrointestinal smooth muscle tumors like leiomyomas and schwannomas [7].

GISTs express an uncertain clinical behavior that ranges from benign to malignant, and there is no any rule of staging system developed yet. The various features of the tumor like initial size, anatomical location, mitotic activity, histologic subtype, presence/absence of intra-tumoral necrosis and age of the patient were suggested as criteria for the disease prognosis [1]. In tumors with a high mitotic rate, features like the presence of an ulcerative lesion, direct organ invasion, infiltration of the mesenteric fat and metastasis are more frequently observed but small bowel GISTs have a higher tendency to show malignant behavior in comparison with those of the stomach. Another report shows that GISTs with irregular borders or tumorous ulcers on endoscopy have the high potential to become malignant [8]. Tumors with a size larger than 5 cm have poor prognosis resulting decreased survival rate and increased chances of metastasis. However, the mitotic activity remains one of the the strongest prognostic factors for GIST [9]. The tumor presented in our case belongs to the category determined by size between 2-5 cm and a mitotic count < 5/50 HPF, which is classified as “low risk”.

The duodenum is not a common site for GIST. Duodenal GIST is usually asymptomatic when its size is small and can develop to a larger size before being symptomatic. The most common features are abdominal pain and upper gastrointestinal bleeding (hematemesis) which may be chronic and mild or massive [10]. Since the tumor size of our patient was not so large, he didn't have any such peculiar features suggestive of GIST.

Diagnosis of the GISTs can be achieved with upper gastrointestinal endoscopy [11]. The tumor shows exophytic growth pattern and gives an appearance of submucosal swelling. Sometimes, it may be present with an ulcer only. While performing tissue biopsy, it should be deep, but it may not always be diagnostic. Endoscopic ultrasound can be reliable in diagnosing the submucosal tumor. Other diagnostic modalities include CT scan and magnetic resonance imaging (MRI) [12] which have become the best choice for the assessment of the primary lesion and detection of metastases. In a CT scan, the features of GISTs vary greatly, depending on the size and aggressiveness of the tumor mass and the time of presentation during the course of the disease. Primary GISTs are typically large, enhancing masses on contrast-enhanced CT scans and are often heterogeneous with central low density due to necrosis, hemorrhage or cystic degeneration at the time

of presentation. The masses usually displace adjacent organs and vessels, but direct invasion of the adjacent structures is sometime seen with advanced diseases. In case duodenal GIST, CT scan usually shows the tumor mass at the site of the duodenum and head of the pancreas and make it unreliable in diagnosing the origin of the mass. On various instances, the mass was misdiagnosed as arising from the head of the pancreas [12, 13]. Similarly, our case had been misdiagnosed as carcinoma of head of pancreas in accordance to the findings of CT scan. In MRI T1weighted images show low signal intensity solid component and the enhancement is usually present peripherally in larger lesions. T2 weighted images show high signal intensity solid component.

The treatment of GIST depends upon the size of tumor [14]. For small tumors, complete surgical excision can be performed by local or segmental duodenal resection with preservation of the pancreas [14]. And for larger tumors, pancreaticoduodenectomy is required. The surgical choice depends not only on the size but also on the location of the lesion in the duodenal wall and its relation to the ampulla of Vater [15]. The optimal surgical margin is not clear but including few centimetres of the normal tissues will be better to prevent local recurrence of the tumor. Lymph node dissection is not necessary to perform routinely since their involvement is infrequent [16, 17]. Patients with duodenal GISTs close to the ampulla of Vater should be treated by pancreatoduodenectomy. Various techniques of limited resection for duodenal GISTs have been implemented, depending on the site and the size of the tumors. The outcome depends on the pathological features of the tumor and the nature of surgical resection whether it is complete or not. Large tumors with high mitotic counts act much worse than small tumors with low mitotic counts. Chance of recurrence is higher in tumors which are not completely resected or with a positive microscopic margin.

Adjuvant therapy is the modality of treatment for locally advanced or metastatic or high risk GIST (Tumor size > 10 cm, mitotic count > 10/50 HPF, and tumor rupture), under which imatinib is administered. Imatinib is a signal transduction inhibitor that especially inhibits the binding of adenosine triphosphate to tyrosine kinase which includes PDGFRA and the c-Kit receptor expressed in GISTs [18]. Recently sunitinib malate, an oral receptor tyrosine kinase inhibitor, was approved for the treatment of GISTs for those who are intolerant to imatinib. Sunitinib inhibits platelet-derived growth factor receptors and vascular endothelial growth factor receptors, which play key roles in tumor angiogenesis and tumor cell proliferation [19]. In case of development of sunitinib resistance, a novel drug namely Regorafenib has come to practice, which is an oral multikinase inhibitor that blocks the activity of multiple protein kinases, including those involved in the regulation of tumour angiogenesis, oncogenesis and the tumour microenvironment [20]. As our patient was classified as "low risk" duodenal GIST, adjuvant treatment was not necessary.

In summary, we report a case of a rare duodenal GIST mimicking pancreatic head tumor, treated successfully by wedge resection. The patient has been doing well without recurrence since surgery, and we will continue to monitor him with a strict follow-up schedule.

## CONCLUSION

Duodenal GIST should be suspected in any patient with a duodenal wall mass. It is usually asymptomatic when small in size and can progress to a larger size before being symptomatic. It can be revealed as an incidental finding while performing CT scan for any other reasons. And, CT scans are not always helpful in specifying the origin of the mass as it sometimes mimics pancreatic head tumor with duodenal GIST. Hence, we need to be very careful while dealing a patient with such imaging findings. There is more than one surgical approach available, but the absolute requirement is complete surgical excision. Preoperative Imatinib can be considered in unresectable or borderline resectable cases.

## REFERENCES

1. Cao, H., et al., *Prognostic analysis of patients with gastrointestinal stromal tumors: a single unit experience with surgical treatment of primary disease*. Chin Med J (Engl), 2010. **123**(2): p. 131-6.
2. Hamzaoui, L., et al., *Gastrointestinal stromal tumours (GISTs): A descriptive study on 29 cases*. Arab J Gastroenterol, 2016. **17**(4): p. 185-187.
3. Abedalthagafi, M., *Gastrointestinal stromal tumour originating from the hepatic falciform ligament*. BMJ Case Rep, 2012. **2012**.
4. Munoz, M., et al., *Gastrointestinal stromal tumors as an incidental finding in patients with a presumptive diagnosis of ovarian cancer*. J Gynecol Oncol, 2012. **23**(1): p. 48-52.
5. Catena, F., et al., *Microscopic margins of resection influence primary gastrointestinal stromal tumor survival*. Onkologie, 2012. **35**(11): p. 645-8.
6. Ud Din, N., et al., *Gastrointestinal Stromal Tumors: A Clinicopathologic and Risk Stratification Study of 255 Cases from Pakistan and Review of Literature*. Asian Pac J Cancer Prev, 2015. **16**(12): p. 4873-80.
7. Lee, S.J., et al., *Gastrointestinal tract spindle cell tumors with interstitial cells of Cajal: Prevalence excluding gastrointestinal stromal tumors*. Oncol Lett, 2016. **12**(2): p. 1287-1292.
8. Nishida, T., et al., *Submucosal tumors: comprehensive guide for the diagnosis and therapy of gastrointestinal submucosal tumors*. Dig Endosc, 2013. **25**(5): p. 479-89.
9. Demir, L., et al., *Does immunohistochemistry provide additional prognostic data in gastrointestinal stromal tumors?* Asian Pac J Cancer Prev, 2013. **14**(8): p. 4751-8.
10. Fang, Y., et al., *[Clinicopathological analysis of 80 patients with duodenum gastrointestinal stromal tumors]*. Zhonghua Wei Chang Wai Ke Za Zhi, 2015. **18**(1): p. 26-9.
11. Cavallaro, G., et al., *Duodenal gastrointestinal stromal tumors: review on clinical and surgical aspects*. Int J Surg, 2012. **10**(9): p. 463-5.
12. Dimitrakopoulou-Strauss, A., et al., *Imaging therapy response of gastrointestinal stromal tumors (GIST) with FDG PET, CT and MRI: a systematic review*. Clin Transl Imaging, 2017. **5**(3): p. 183-197.
13. Singh, S., et al., *Duodenal GIST presenting as large pancreatic head mass: an uncommon presentation*. Jop,

2012. **13**(6): p. 696-9.
14. Hou, Q., et al., [*Analysis of gastric gastrointestinal stromal tumors in Shandong Province: a midterm report of multicenter GISSG1201 study*]. *Zhonghua Wei Chang Wai Ke Za Zhi*, 2017. **20**(9): p. 1025-1030.
  15. Rabin, I., et al., *Gastrointestinal stromal tumors: a 19 year experience*. *Isr Med Assoc J*, 2009. **11**(2): p. 98-102.
  16. Sakata, K., et al., [*Local resection and jejunal patch duodeno-plasty for the duodenal gastrointestinal stromal tumor--a case report*]. *Gan To Kagaku Ryoho*, 2009. **36**(12): p. 2348-50.
  17. Buchs, N.C., et al., *Segmental duodenectomy for gastrointestinal stromal tumor of the duodenum*. *World J Gastroenterol*, 2010. **16**(22): p. 2788-92.
  18. Caram, M.V. and S.M. Schuetze, *Advanced or metastatic gastrointestinal stromal tumors: systemic treatment options*. *J Surg Oncol*, 2011. **104**(8): p. 888-95.
  19. Demetri, G.D., et al., *Efficacy and safety of sunitinib in patients with advanced gastrointestinal stromal tumour after failure of imatinib: a randomised controlled trial*. *Lancet*, 2006. **368**(9544): p. 1329-38.
  20. Wilhelm, S.M., et al., *Regorafenib (BAY 73-4506): a new oral multikinase inhibitor of angiogenic, stromal and oncogenic receptor tyrosine kinases with potent preclinical antitumor activity*. *Int J Cancer*, 2011. **129**(1): p. 245-55.