



## **REVIEW ON FIBROADENOMA**

\*Roshan Kumar Yadav, Prof. Zeng Jin Min, Sanjay Kumar Verma, Shashi Kumar Yadav,  
Abhinandan Gupta and Dipaka Dhakal

*Department of Medicine, Clinical College of Yangtze University, The second affiliated Hospital to Yangtze  
University, Jingzhou, P. R. China.*

*Department of Respiratory Medicine, The first affiliated Hospital to Yangtze University, Jingzhou, P.R. China.*

### **ABSTRACT**

A fibroadenoma, is a painless benign breast tumours characterized by a mixture of stromal and epithelial tissue. Breasts are made of lobules (milk producing glands) and ducts (tubes that carry the milk to the nipple). They are formed by glandular, fibrous and fatty tissue. Fibroadenomas develop from the lobules. The glandular tissue and ducts grow over the lobule to form a solid lump. It occurs most commonly in women between the age of 14 to 35 years but can be found at any age. Fibroadenomas shrink after menopause, and therefore, are less common in post-menopausal women. Fibroadenomas are often referred to be a breast mouse due to their high mobility. Fibroadenomas are a marble-like mass comprising both epithelial and stromal tissues located under the skin of the breast. These are firm, rubbery masses with regular borders and are often variable in size. Fibroadenomas are of four types; complex, Juvenile, Giant fibroadenoma and phyllodes tumor. Complex fibroadenoma contain rapidly growing hyperplastic cells; the pathologist can establish diagnosis after carefully reviewing the biopsy of breast tissue. Juvenile fibroadenoma [1, 2] is commonly found in patients age 10 to 18 years. These fibroadenomas have a faster growth rate and eventually shrink or disappear. Giant fibroadenomas are non-cancerous lesions that are slightly larger than other types. They commonly need excision because they compress or replace normal breast tissue. Phyllodes tumor are the stromal cell tumors.

## INRODUCTION

A fibroadenoma is a painless, unilateral, benign (non-cancerous) breast tumor that is a solid, not fluid-filled, lump. It occurs most commonly in women between the age of 14 to 35 years but can be found at any age. Fibroadenomas shrink after menopause, and therefore, are less common in post-menopausal women. Fibroadenomas are often, referred to be a breast mouse due to their high mobility. Fibroadenomas are a marble-like mass comprising both epithelial and stromal tissues located under the skin of the breast. These are firm, rubbery masses with regular borders are often variable in size.

### **Types:**

#### **Complex Fibroadenoma:**

Rapidly growing hyperplastic cells; the pathologist can establish diagnosis after carefully reviewing the biopsy of breast tissue

#### **Juvenile Fibroadenoma:**

This fibroadenoma is commonly found in patients age 10 to 18 years. These fibroadenomas have a faster growth rate and eventually shrink or disappear.

#### **Giant Fibroadenoma:**

This non-cancerous lesion is slightly larger than other types. It commonly needs excision because it compresses or replaces normal breast tissue.

#### **Phyllodes Tumor:**

A stromal tumor of the breast that can be either benign or malignant. It is not a fibroadenoma, therefore; it needs to be watched closely. Most doctors recommend removing it.

### **Etiology:**

Causes of fibroadenoma are debatable, but professionals believe that the lesion has a hormonal etiology related to the increased sensitivity of breast tissue to the female reproductive hormone estrogen. Fibroadenoma usually grows during pregnancy and tends to shrink during menopause. This supports the hormonal etiologic theory. Females who take oral contraceptives before 20 years of age tend to suffer from fibroadenoma at higher rates than the general population.

### **Epidemiology:**

Fibroadenoma tends to occur in early age. It is most commonly found in adolescents and less commonly found in postmenopausal women. The incidence of fibroadenoma decreases with increasing age and generally found before 30 years of age in females in the general population. It is estimated that 10% of the world's female population suffers from fibroadenoma once in a lifetime.

### **Pathophysiology:**

#### **Hormonal:**

Fibroadenoma arises from stromal and epithelial connective tissue cells that are functionally and mechanically important in the breast. These tissues contain receptors for both estrogen and progesterone. For

this reason, fibroadenomas tend to proliferate during pregnancy because of excessive production of female reproductive hormones. Hormone sensitivity causes excessive proliferation of breast connective tissues.

#### **Genetics:**

Mediator complex subunit 12 (*MED12*) gene is also important in the pathophysiology of fibroadenomas.

#### **Histopathology:**

The histological diagnostic features of fibroadenoma can be described as sheets of uniformly distributed epithelial cells that are typically arranged in a honeycomb pattern. There is a presence of foam cells and apocrine cells and an absence of excessive mitotic activity or anaplasia. Calcification may also be present. Juvenile fibroadenoma has increased in stromal cellularity. The stroma is hypovascular as compared to the malignant neoplasms. The basement membrane also remains intact in fibroadenoma which reflects its benign feature.

#### **Microscopic Features:**

##### **Contains both stromal and epithelial tissues that are arranged in 2 patterns:**

1. **Pericanalicular:** Includes the proliferation of stromal cells around epithelial structures
2. **Intracanalicular:** Includes the proliferation of stromal cells compressing epithelial cells into clefts

##### **Unique Histological Features of Various Fibroadenomas**

1. **Complex fibroadenoma:** Sclerosing adenosis, calcification, apocrine metaplasia.
2. **Juvenile fibroadenoma:** Epithelial and stromal hyperplasia, absence of mitoses, thin micropapillae.
3. **Myxoid fibroadenoma:** Stroma has myxoid features

#### **History and Physical:**

Age is the most important factor in the incidence of fibroadenoma. Therefore, when obtaining a medical history, age is the most important factor that should be considered. A family history of breast cancer is also significant. Female patients who have first-degree relatives with breast cancer should be monitored and observed more carefully for malignant features than patients without this family history. Fibroadenoma most commonly occurs in the upper outer quadrant of the breast. On physical examination, it has the following features:

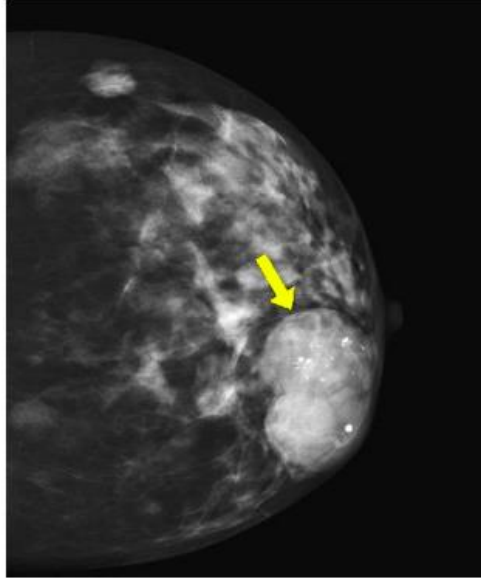
- ❖ Non-tender or painless
- ❖ Mobile
- ❖ Solitary
- ❖ Rapidly growing solid lump with rubbery consistency and regular borders.

#### **Evaluation:**

After a thorough history and physical examination, the following imaging modalities are used for the diagnosis of fibroadenomas.

### **Diagnostic Mammogram:**

A mammogram uses x-rays to evaluate the suspicious masses in women above 35 years of age. Fibroadenoma on a mammogram appears as a distinct area from other breast tissue, with smooth round edges. See figure 1.



**Figure 1:** Fibroadenoma on mammogram.

Mammographic features of fibroadenomas are variable from a well-circumscribed discrete oval mass hypodense or isodense of breast glandular tissue to a mass with macro lobulation or partially obscured margins. Involuting fibroadenomas in older, typically postmenopausal patients may contain calcification, often producing the classic, coarse popcorn calcification appearance.

### **Breast Ultrasound[3][4]:**

Ultrasound (US) uses sound waves to detect the features of fibroadenomas in women younger than 35 years of age. US easily differentiates solid from the cystic masses. On US, fibroadenoma mass is typically seen as a well-circumscribed, round to ovoid, or macrolobulated mass with generally uniform hypoechogenicity. If necessary, a minimally invasive biopsy may be performed via a core needle biopsy[5]

### **Treatment:**

In the majority of cases, fibroadenomas need no treatment. They shrink and disappear over time, but if their size is large and they are compressing other breast tissues, they should be removed. Many females decide against the surgery because the lesions are harmless and involve no long-term risk of malignancy. Surgery also distorts the shape of a breast.

### **Surgery:**

Doctors might decide to remove fibroadenoma if it is massive and continues to increase in size. Indications for surgical intervention include rapid growth, size greater than 2 cm, and patient request.

There are 2 surgical procedures used to remove a fibroadenoma:

1. **Lumpectomy or excisional biopsy:** In this procedure, the surgeon removes the fibroadenoma and sends it to the laboratory for further evaluation.
2. **Cryoablation:** Surgeons use a cryoprobe to freeze and destroy the cellular structure of fibroadenoma. A core needle biopsy must be performed before cryoablation to confirm the fibroadenoma.

### **Differential Diagnosis:**

A fibroadenoma can be confused with:

- ❖ Breast cyst
- ❖ Breast carcinoma
- ❖ Phyllodes tumor
- ❖ Breast lymphoma
- ❖ Metastasis to the breast from another primary site

### **Prognosis:**

Prognosis of fibroadenoma is good because it is a benign mass which shrinks in size over time in the majority of cases.

### **Complications:**

Breast cancer risk may slightly increase in patients with a complex fibroadenoma. This type of lesion may contain calcified breast tissue.

## **CONCLUSIONS**

Fibroadenoma has been the most common benign breast disease, though not dangerous by itself but has tendency to become malignant. Its management is not so tough. So, there is in need of more research into the picture of breast disease in the country, covering various demographic characteristics of the country's population for all regions and informing about its incidence rates and prevalence and also the breast cancer risk estimate for benign breast disease.

## **REFERENCES**

1. Ajmal, M. and K. Van Fossen, *Breast Fibroadenoma*, in *StatPearls*. 2018, StatPearls PublishingStatPearls Publishing LLC.: Treasure Island (FL).
2. Woodard, S., S. Schetter, and K. Millington, *Diagnosis and imaging characteristics of a juvenile fibroadenoma in a 2-year-old patient: a case report*. *Radiol Case Rep*, 2018. **13**(1): p. 6-10.
3. Namazi, A., et al., *An Evaluation of Ultrasound Features of Breast Fibroadenoma*. *Adv Biomed Res*, 2017. **6**: p. 153.
4. Huang, I.C., P.C. Li, and D.C. Ding, *Recurrent juvenile fibroadenoma of the breast in an adolescent: A case report*. *Medicine (Baltimore)*, 2018. **97**(20): p. e10765.
5. Giannos, A., et al., *A prepubertal giant juvenile fibroadenoma in a 12-year-old girl: Case report and brief literature review*. *Int J Surg Case Rep*, 2017. **41**: p. 427-430.