



## ROLE OF STEROID IN TUBERCULAR PLEURAL EFFUSION: A CASE REPORT

Dr. Xia Wei, Dr. Prakash Shrestha and Prof. Xiao Wei

*Pulmonary and Critical care department, Jingzhou number 1 people's hospital, Jingzhou, P. R China*

### ABSTRACT

Tuberculosis is one of the most common disease in developing world with its pulmonary and extra pulmonary forms. The treatment of tubercular pleural effusion is full of controversies, especially in the use of glucocorticoid. This case study shows the dramatic improvement with the use of glucocorticoid along with ATT. So, this case supports the aid in use of steroid in Tubercular pleural effusion in young those who are not responding to ATT along with multiple thoracocentesis which can also prevent the fibrotic scar in lung.

**Key words:** TPE, TB, ATT, Glucocorticoid, ADA,

## INTRODUCTION

Tuberculosis (TB) is a disease of great antiquity. It is a leading cause of preventable morbidity and mortality from an infectious agent worldwide. Though pulmonary TB is the most common presentation of *M. Tuberculosis* infection, extra-pulmonary TB also constitutes a frequent clinical problem, particularly due to advancing immunosuppressant in the present world of HIV infection. A pleural effusion occurs in approximately 5% of patients with TB. A definite diagnosis of TPE can be difficult to make because of low sensitivity and/or specificity of noninvasive traditional diagnostic tools. Gold standard for diagnosis of pleural tuberculosis is the identification of *M. tuberculosis* in pleural fluid and tissue. But in practice, this identification is problematic because of low identification rate of bacillus (less than 30% in the pleural fluid and approximately 50% in the pleural tissue) and slow growth of mycobacterium in culture (about 60days). Direct analysis of pleural fluid for detection of acid-fast bacilli (AFB) by Ziehl-Neelsen or similar method is positive in less than 5% of cases and culture on Löwenstein-Jensenmedium does not surpass a 40% positivity rate. Moreover, direct examination of pleural fluid with Z-N staining requires bacillar concentration of 104/ml to be positive, but mycobacterial load in pleural fluid is very low. Moreover, culture is time consuming, requires 4-6 weeks to yield growth of *M. tuberculosis*, even with radiometric mycobacterium culture system (BACTEC), which takes 18 days. Moreover cultures require a minimum of 10 to 100 viable bacilli. On the other hand, pleural biopsy demonstrates granulomatous pleuritis in 50-80% of patients with TPE and when a culture of biopsy specimen is combined with histological examination, the diagnosis can be established in approximately 90% of cases. Sometimes, in absence of granuloma, examination of biopsy specimen for AFB revealed organism in 10% of cases. Histopathology of pleural biopsy is superior to all the conventional test and is the specimen of choice for the diagnosis<sup>14</sup>, but the risk of complications from thoracentesis, cost of patient care, the presence of a physician who is trained to perform the procedure and appropriate facilities for its performance, as well as a pathological laboratory and a experienced pathologist who can interpret the finding all make the diagnostic procedure difficult. It does not always guarantee the collection of representative sample. Moreover, it is fully a blind invasive procedure.

Sputum specimens are often not evaluated because many of these patients are not able to produce sputum spontaneously. The sputum cultures are positive in 30-50% patients with both pulmonary and pleural tuberculosis but are positive in only 4% of patients with isolated pleural effusion.

In this context, difficulty in diagnosing tuberculous pleural effusion led to a simple, rapid, cost effective method that would optimize workup of those patients. Adenosine deaminase assay may be very useful diagnostic approach for the diagnosis of tubercular pleural effusion in combination with other diagnostic.

Tuberculous pleurisy has been treated with a combined regimen of corticosteroids-antimicrobial therapy since the middle half of this century. Most of the published articles are in general agreement that such combination therapy causes more rapid clinical improvement and absorption of pleural fluid. However,

its routine application to patients with tuberculous pleurisy remains controversial. In addition, most reported clinical trials were performed in the 1960s when the treatment of tuberculosis had not been fully developed. With the modern multi-drug regimen, extrapulmonary as well as pulmonary tuberculosis can be eradicated more. No well-controlled study has been undertaken, to our knowledge, to determine the role of corticosteroids in the treatment of tuberculous pleurisy. Whether corticosteroids add benefits to modern antimicrobial therapy in these patients is unknown.

### **CASE STUDY**

A 17 years old boy from Hubei province, a Chinese Resident, presented in our emergency department with history of right sided chest pain from last 15 days which was non – radiating in nature but gives history of right sided chest heaviness, pain was pricking in nature mostly during inspiration and was increasing in nature. It was associated with dry cough. Cough exacerbates during forceful inspiration. He denies history of trauma or ingestion of new foods recently. He has no history of contact with pets. It was followed by fever, which was mild and evening rise in nature from last 7 days but he denies history of chills or rigor. Fever was intermittent in nature and have the spikes at evening. He has normal bladder and bowel habit. There is no history of recent travel. He also experienced decreased appetite associated with fever but there is no significant history of weight loss or dysphagia.

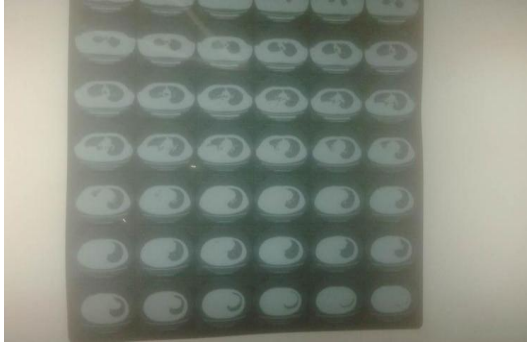
He has history of smoking 10 sticks per day cigarette for 2 years and quit it 15 days back after the occurrence of this problem. He is an athlete and he is not immunocompromised prior to this illness.

His grandfather was treated with ATT therapy and his father has a fibrotic scar in right lung negative for Tuberculosis.

#### **On examination:**

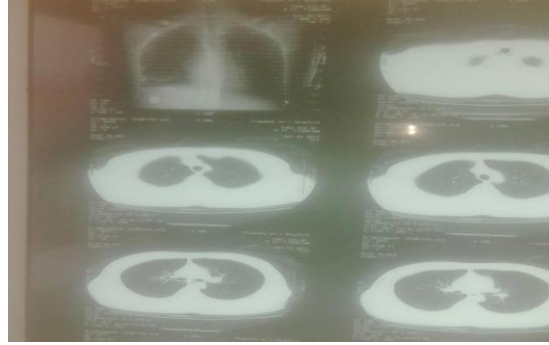
He is fully oriented to time place and person. There is no evidence of pallor, anemia, lymphadenopathy nor clubbing. His Respiratory system revealed: Inspection: no scar, no deformity, however, expansion of chest was less on the left side. Palpation revealed: There is decreased vocal fremitus on the right side from 4<sup>th</sup> intercostal space. Percussion Revealed: There is presence of stony dullness starting from the right 4<sup>th</sup> intercostal space till the liver dullness. Auscultation revealed: There is decreased air entry on the right side but no evidence of adventitia, whereas, there is normal Vesicular breathe sound in the left side.

Cardiac examination revealed: Apex beat present at 5<sup>th</sup> ICS at the line of anterior axillary line. There is no evidence of murmur. Other systemic examination revealed normal findings.



ON the day of admission

Right sided Pleural effusion



After treatment

fluid has decreased dramatically

## DISCUSSION

With the provisional diagnosis of right sided pleural effusion , CT Chest was performed which was evident of unilateral moderate pleural effusion. His laboratorial value of serum showed High ESR, normal CBC , RFT , LFT . The viral markers and test for influenza, RSV, LP1, MP all revealed negative. He was then planned for diagnostic as well as therapeutic thoracocentesis with full evidence of normal blood coagulation profile and the fully explained written consent was taken from his father. 600ml of straw coloured fluid was aspirated under local anaesthesia and sent for laboratorial investigations. His pleural fluid analysis revealed exudative pleural effusion , according to Light's criteria. His pleural fluid report was evident of lymphocyte predominant 90% and Very high ADA( 61.5IU/L), however, gram stain and AFB stain were negative. With evidence of high ESR, high ADA and lymphocyte predominance , he was started on ATT regimen with triple therapy( Rifampicin+ Isoniazid + Ethambutol), alongwith Pyridoxine, after the evidence of normal liver function test. Despite of ATT , there was no marked improvement , however , the fever was subsided after the use of ATT. SO, USG chest was done and revealed marked pleural effusion on the right , so , therapeutic tapping was performed on the third day of ATT. After on, clinically he became better but there was still presence of marked pleural effusion. Hence, thoracocentesis was continuously performed . within period of week he underwent for multiple thoracocentesis . Despite all the measure , he was not responding as expected . So, considering the fact the exudative may produce superimposed infection as well as dreadful conditions like pulmonary fibrosis in such an young age , weighing the dubious use of glucocorticoid , he was started on low dose glucocorticoid . After 3 doses of steroid, his pleural effusion dramatically decreased. He was closely observed for 2 weeks and got discharged on ATT and steroid to continue follow up in hospital. Follow up CT scan of chest showed marked improvement with clinically asymptomatic. Hence, the use of steroid in TPE can help to prevent fibrosis of lung and most importantly it will decrease the use of chest tube

insertion ,which may cause unwanted discomfort and injury to pleura and lung leading to further complications.

### CONCLUSION

The treatment of tubercular pleural effusion is still a concern of controversy whether to use ATT alone or combination with glucocorticoid. There are lots of ideas regarding the treatment protocol for TPE. But our case study has proven that the adjunctive use of steroid with ATT had responded dramatically to decrease the pleural effusion and clinical comfort. Hence, the use of corticosteroid along with ATT will be worthy to continue, which will decrease the chance of pulmonary fibrosis in such a young ones.

### REFERENCES

1. Corticosteroid in the treatment of tuberculous pleurisy, A double blind placebo-controlled , randomized study, C H Lee; W J Wang; R S Lan; Y H Tsai; Y C Chiang, *Chest*. 1988;94(6):1256-1259. doi:10.1378/chest.94.6.1256
2. Role of Corticosteroids in the Treatment of Tuberculosis: An Evidence-based Update, Tamilarasu Kadiravan and Surendran Deepanjali, Department of Medicine, Jawaharlal Institute of Postgraduate Medical Education and Research, Puducherry, India
3. Adenosine Deaminase (ADA) Level in Tubercular Pleural Effusion S.K. Verma, A.L. Dubey, P.A. Singh, S.L. Tewerson, and Davashish Sharma