



TRANSFORAMINAL PERCUTANEOUS ENDOSCOPIC LUMBAR DISCECTOMY (TPELD) IN TREATMENT OF LUMBAR DISC HERNIATION

Dr. Mani Thapa Magar*, Prof. Dr. Xu Yongtao, Dr. Ma Liang and Dr. Wang Yonggang

*Department of Orthopaedics, Clinical Medical College of Yangtze University, Jingzhou Central
Hospital, JingZhou, Province-Hubei, P.R.China*

ABSTRACT

Lumbar disc herniation is a most common cause of back pain and sciatica. The patients who are not relieved by conservative treatment are considered for surgical intervention. Currently there are numerous surgical interventions for lumbar disc herniation. They are broadly classified as posterior open technique and percutaneous endoscopic techniques. In recent years, transforaminal percutaneous endoscopic lumbar discectomy is being widely popular. Between open technique and percutaneous endoscopic technique, percutaneous endoscopic technique is found to be more safer, effective with higher satisfactory results due to low complication rate, less hospital stay, less invasive, and early return to normal life. The main aim of this review is to evaluate the efficacy, indications and contraindications and complications of transforaminal percutaneous endoscopic lumbar discectomy and its advantages in clinical basis.

Keywords: Transforaminal percutaneous endoscopic lumbar discectomy (TPELD), Lumbar disc herniation (LDH), Open technique, Visual analogue scale (VAS)

INTRODUCTION

Lumbar disc herniation is a major cause of back pain and sciatica which has been one of the most common and disabling spinal disorders[1].The incidence of symptomatic LDH in the United States is 1% to 2%[2].Approximately 70%-80% of people experiences back pain during their lives.The prevalence of herniated discs are higher among people 35-45 years old[3].Many epidemiological studies have suggested that the increasing incidence of intervertebral disc disease among population including young is due to lack of physical activities and sedentary life style.

For patients with LDH who donot achieve satisfactory recovery following conservative treatment are considered for surgical intervention.The surgical management of LDH has evolved from exploratory laminectomy to percutaneous endoscopic discectomy.Among all,tranforaminal percutaneous endoscopic lumbar discectomy(TPELD) is growing popularity as it is performed under direct endoscopic vision with maximum satisfactory results.Kambin and Gellman introduced the percutaneous arthroscopic posterolateral extracanal approach for treating LDH[4].Since then,many surgeons have developed new techniques for percutaneous endoscopic discectomy.Most current percutaneous discectomy techniques are based on the Kambin's tranforaminal approach and offers favorable outcomes for disc herniation[5-7].Now, due to advancement of techniques and equipments including endoscopes and side-firing Ho:YAG laser,the range of indications for Transforaminal percutaneous endoscopic lumbar discectomy has broadened.

SURGICAL TECHNIQUE

The posterolateral approach involves accessing the triangular working zone originally described by Kambin and Gellman.This zone provides safe access to both the foramen and the intradiscal space.The zone is bounded superiorly and anteriorly by nerve root,inferiorly by transverse process, and medially by the superior facet.

The surgery is performed under local anesthesia in the prone position on a radiolucent operating table on a Wilson frame with a 30 degree flexion of the hip and knee joints .This lowers the chance of epidural bleeding.The midline is marked on the skin surface by palpating the spinal processes.Then a transverse line bisecting the disc is drawn along the K-wire which is placed transversely across the center of the target disc on the posteroanterior image.The surface marking of anatomic disc center is identified by the intersection of transverse line and longitudinal midline,which is used as the aiming reference point of puncture.

The skin incision is made approximately 8-14cm from the midline.An 18-gauge spinal needle is inserted under fluoroscopic guidance after infiltrating the entry point with local anesthetics.The needle is inserted at about 35degree angle(25-45 degree) to the horizontal plane.The ideal target point of the spinal needle is the intersection of the posterior vertebral line on the lateral image and the medial pedicular line on

the anteroposterior image. After introduction of the spinal needle into the target disc space, we inserted the guide wire through the spinal needle and then spinal needle is removed leaving the guide wire in situ. A stab incision of about 6mm is made at the entry point. A 2mm conical rod is introduced over the guide wire and then sequentially the first, second and third sleeves are inserted dilating the soft tissues upto 6.5mm. Then the reamer is introduced anticlockwise to avoid damage to the spinal muscles and continuously under the guidance of image intensifier reamed to 1 or 2mm inside the medial pedicular line. The procedure is repeated with each of the sequentially larger rods, tubes and reamers. Then working cannula is introduced over the third conical rod and its tip should be located on the herniated disc. Then image intensifier is removed and working endoscope set introduced and herniated disc removed under direct visualization as seen in **FIGURE 1**. After complete decompression, the dural sac and the lumbar exiting nerve root is checked for freely movable with the valsalva maneuver. Bleeding of the small vessels is controlled with a flexible bipolar radiofrequency probe. Communication with patients is maintained throughout the procedure. Finally, the endoscope is removed, the incision is sutured and a sterile dressing is applied.

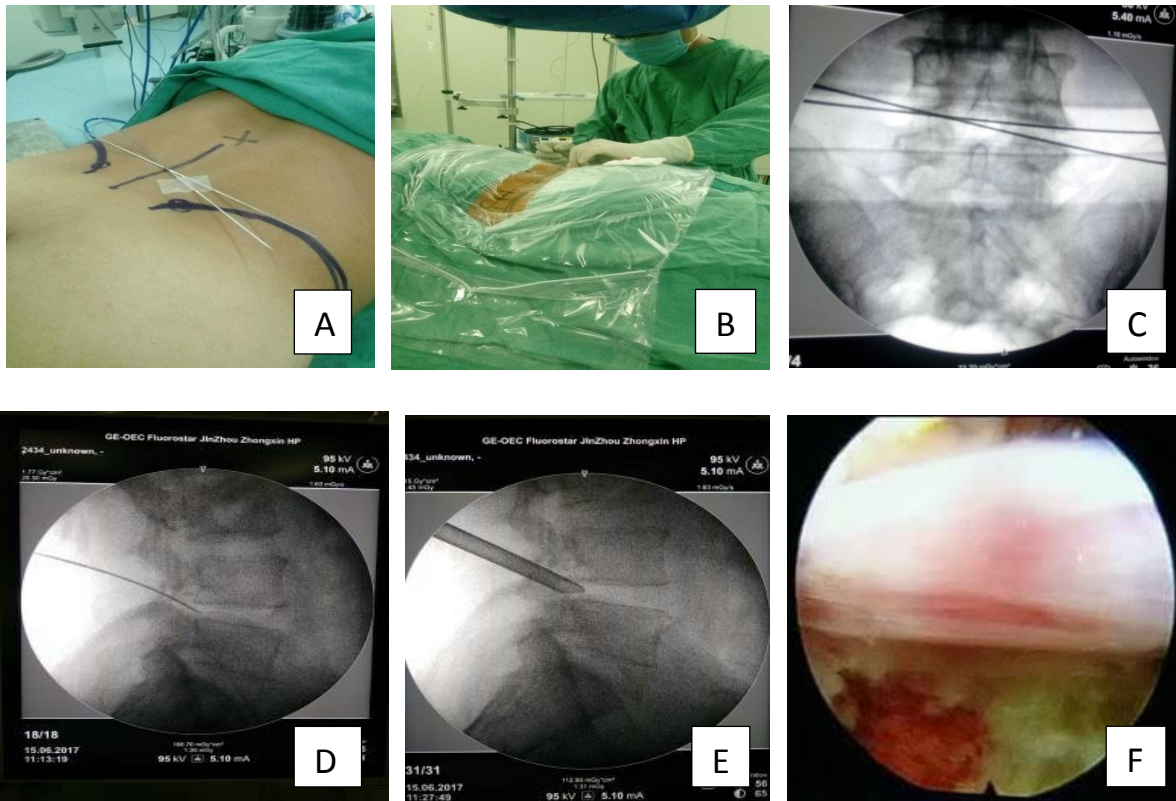


Figure 1: Procedure for Transforaminal percutaneous endoscopic lumbar discectomy. A) marking of vertical and transverse line, B) infiltrating of local anesthetics at entry point, C) identifying the target disc on C-arm, D) insertion of 18-gauge needle, E) insertion of dilator, F) free nerve root after discectomy

DISCUSSION

Although the reported outcomes of TPELD are generally good, this technique requires numerous endoscopic techniques and thus has a steep learning curve. The outcomes are heavily dependent on the surgeon's skills. The outcome of TPELD are evaluated by modified MacNab criteria (table 1), visual analog scale (VAS 0-10), Oswestry Disability Index (ODI 0-100%).

Based on the modified MacNab criteria, study done by Wen-Ching Tzaan showed 28% of excellent, 61% good, 7% fair and 4% poor outcomes [8]. Yu-tong Gu et al. reported significant drop in VAS score of leg pain from 9 (6-10) before operation to 1 (0-3) ($p < 0.001$) immediately after the operation and to 0 (0-3) ($p < 0.001$) 2 years after operation. At 2 year followup, 95% of the patients showed excellent or good outcomes, 2.9% fair and 1.4% poor [9]. Another study done by Yong Ahn et al. showed the improvement of mean preoperative VAS score for back pain from 5.36 (SD=2.09) to 3.15, 2.61, 2.12 and finally 2.09 (SD=1.77) at postoperative 6 weeks, 6 months, 1 year and 2 years respectively ($p < 0.001$). And the mean preoperative ODI score from 65.8% (SD=17.4%) to 31.6%, 28.0%, 19.7% and finally 19.3% (SD=16.7%) at postoperative 6 weeks, 6 months, 1 year and 2 years respectively ($p < 0.001$) [10]. Some studies have shown that the outcome based on MacNab criteria can be different based on age whereas there is no such difference in outcome based on age and sex of patients in ODI and VAS score [11, 12].

Results	Complications
Excellent	No pain, no restriction of activity
Good	Occasional back pain or leg pain not interfering with the patient's ability to do his or her normal work or to enjoy leisure activities
Fair	Improved functional capacity but handicapped by intermittent pain of sufficient severity to curtail or modify work or leisure activities
Poor	No improvement or insufficient improvement to enable an increase in activities /or further operative intervention required

Table 1: MacNab Classification

Indications/Contraindications:

Indications:

1. Persistent radicular pain, numbness, or weakness caused by disc herniation compromising root or roots confirmed by CT, MRI, myelogram or discogram
2. Positive tension or compression signs, or motor, sensory or reflex abnormalities
3. Not responding to conservative treatment

4. Extruded discs and free fragments
5. Obese or poor health so that open surgery would be an increased risk

Contraindications:

1. Spinal stenosis including lateral lumbar spinal canal stenosis unless root compromise by disc
2. Bony spurs, facet hypertrophy, or ligamentous hypertrophy causing neurologic symptoms
3. Significant spinal instability
4. Inaccessible free fragment or fragments
5. Calcified herniated disc
6. Significant cicatrix or arachnoiditis
7. Inadequate pathway through the foramen

Complications:

Despite many studies have been done regarding the clinical efficacy of TPELD, there are some reports of complications of the surgeries such as dural tear, hematoma collection, residual disc specimen, vascular injury, infection, thrombophlebitis etc [13]. In 2002, Yeung et al. [14] has reported the reoperation rate of 5%. In 2006, the study done by Hoogland et al. [15] showed that there was a recurrence rate of 6.9% at 1 year postoperatively in 142 cases treated with posterior lateral endoscopic discectomy (TESS). Conversion to open technique was seen in 7.8% in study done by Lee et al. 1-2% cases of nerve injury have been reported in some studies [12]. Study by Wang Chen et al. showed 5.9% postoperative dysesthesia [8]. Though few complications have been seen but the rate of complication is very low. So, we still believe this technique is safe to be performed for treatment of the patients.

Advantages of TPELD over Open techniques:

Since the advancement in spinal surgery, various techniques have been developed to treat the spinal problems. In recent times endoscopic procedures are increasingly used for the management of lumbar diseases [16, 17]. Many studies have been done to see outcome between TPELD and open lumbar discectomy. A study done by Chen et al. showed minimal blood loss, decreased hospital stay and mean operating time, immediate postoperative pain improvement in patients with PELD group compared to open lumbar surgery group [18]. Osman et al. [19] reported one comparative study regarding postoperative stability of transforaminal and posterior open approach using cadaver which showed minimal anatomic damage to the spine with no flexibility change in transforaminal decompression group whereas there was significant increase in extension and axial rotation flexibility in posterior open decompression group. The incidence of intraoperative incidental durotomy was reported in 20% of patients who received repeated open lumbar surgery [20-22]. In contrast, considering repeated lumbar surgery by means of PELD, some studies reported

encouraging outcomes. Xia et al.[23], Hoogland et al.[24] and Lee et al.[20] reported that there was no case of intraoperative incidental durotomy or cerebral fluid leakage after surgery in 43,262, and 23 consecutive patients, respectively. Zhimin Pan et al (2016) reported the complication rate for the TESSYS group and open discectomy group were 6.3% and 20.7% respectively showing a notably lower rate in the TESSYS group ($P < 0.01$) [25]. In study done by Yeung and Tsou (2002) reported 89.7% of satisfactory result and 10.3% of poor results in 307 patients treated by posterolateral disc excision [14]. Chen et al. (2009) reported 94.77% satisfactory results with percutaneous endoscopic discectomy in 153 patients with difficult, non-contained lumbar disc herniation [26].

CONCLUSION

TPELD is a safe and effective procedure in lumbar disc herniation. It is less invasive with low complication rate and high satisfactory results in compared to open lumbar surgeries. It has the advantage of performing on a day care basis under local anesthesia with shorter length of hospitalization and early return to work thus improving the quality of life earlier. Due to its advancement in surgical equipments and surgical skills of surgeons, satisfactory results, TPELD has been widely popular in the treatment of lumbar disc surgeries.

Conflict of Interest:

None.

REFERENCES

1. Kambin, P., *History of Surgical Management of Herniated Lumbar Discs From Cauterization to Arthroscopic and Endoscopic Spinal Surgery*, in *Arthroscopic and Endoscopic Spinal Surgery: Text and Atlas*, P. Kambin, Editor. 2005, Humana Press: Totowa, NJ. p. 1-27.
2. DEYO, R.A. and Y.-J. TSUI-WU, *Descriptive Epidemiology of Low-back Pain and Its Related Medical Care in the United States*. *Spine*, 1987. **12**(3): p. 264-268.
3. Heliövaara, M., *Occupation and risk of herniated lumbar intervertebral disc or sciatica leading to hospitalization*. *J Chronic Dis*, 1987. **40**(3): p. 259-64.
4. Kambin, P. and H. Gellman, *Percutaneous Lateral Discectomy of the Lumbar Spine A Preliminary Report*. *Clinical Orthopaedics and Related Research*, 1983. **174**: p. 127-132.
5. Yong Ahn, et al., *Posterolateral percutaneous endoscopic lumbar foraminotomy for L5—S1 foraminal or lateral exit zone stenosis*. *Journal of Neurosurgery: Spine*, 2003. **99**(3): p. 320-323.
6. Hermantin, F.U., et al., *A prospective, randomized study comparing the results of open discectomy with those of video-assisted arthroscopic microdiscectomy*. *JBJS*, 1999. **81**(7): p. 958-65.
7. Parviz Kambin, et al., *Transforaminal arthroscopic decompression of lateral recess stenosis*. *Journal of*

- Neurosurgery, 1996. **84**(3): p. 462-467.
8. Tzaan, W., *Transforaminal percutaneous endoscopic lumbar discectomy*. Chang Gung medical journal, 2007. **30**(3): p. 226.
 9. Gu, Y.-t., et al., *Percutaneous transforaminal endoscopic surgery (PTES) for symptomatic lumbar disc herniation: a surgical technique, outcome, and complications in 209 consecutive cases*. Journal of orthopaedic surgery and research, 2017. **12**(1): p. 25.
 10. Ahn, Y., et al., *Percutaneous endoscopic lumbar foraminotomy: an advanced surgical technique and clinical outcomes*. Neurosurgery, 2014. **75**(2): p. 124-133.
 11. Ahn, S.-S., et al., *Comparison of outcomes of percutaneous endoscopic lumbar discectomy and open lumbar microdiscectomy for young adults: a retrospective matched cohort study*. World neurosurgery, 2016. **86**: p. 250-258.
 12. Wang, K., et al., *Evaluation of transforaminal endoscopic lumbar discectomy in the treatment of lumbar disc herniation*. International orthopaedics, 2015. **39**(8): p. 1599-1604.
 13. Pan, L., P. Zhang, and Q. Yin, *Comparison of tissue damages caused by endoscopic lumbar discectomy and traditional lumbar discectomy: a randomised controlled trial*. International Journal of Surgery, 2014. **12**(5): p. 534-537.
 14. Yeung, A.T. and P.M. Tsou, *Posterolateral endoscopic excision for lumbar disc herniation: surgical technique, outcome, and complications in 307 consecutive cases*. Spine, 2002. **27**(7): p. 722-731.
 15. Hoogland, T., et al., *Transforaminal posterolateral endoscopic discectomy with or without the combination of a low-dose chymopapain: a prospective randomized study in 280 consecutive cases*. Spine, 2006. **31**(24): p. E890-E897.
 16. Gotfryd, A. and O. Avanzi, *A systematic review of randomised clinical trials using posterior discectomy to treat lumbar disc herniations*. International orthopaedics, 2009. **33**(1): p. 11-17.
 17. Li, S., H. Li, and J. Zhao, *Clinical comparison between micro-endoscopic discectomy (MED) and open discectomy for treatment of lumbar disc herniation*. Zhongguo gu shang= China journal of orthopaedics and traumatology, 2008. **21**(5): p. 349-351.
 18. Chen, H.-C., et al., *Comparison of percutaneous endoscopic lumbar discectomy and open lumbar surgery for adjacent segment degeneration and recurrent disc herniation*. Neurology research international, 2015. **2015**.
 19. Osman, S.G., et al., *Transforaminal and posterior decompressions of the lumbar spine: a comparative study of stability and intervertebral foramen area*. Spine, 1997. **22**(15): p. 1690-1695.
 20. Lee, D.Y., et al., *Comparison of percutaneous endoscopic lumbar discectomy and open lumbar microdiscectomy for recurrent disc herniation*. Journal of Korean Neurosurgical Society, 2009. **46**(6): p. 515-521.
 21. Choi, K.B., D.Y. Lee, and S.-H. Lee, *Contralateral reherniation after open lumbar microdiscectomy: a comparison with ipsilateral reherniation*. Journal of Korean Neurosurgical Society, 2008. **44**(5): p. 320-

326.

22. Morgan-Hough, C., P. Jones, and S. Eisenstein, *Primary and revision lumbar discectomy*. Bone & Joint Journal, 2003. **85**(6): p. 871-874.
23. Xia, X.-P., H.-L. Chen, and H.-B. Cheng, *Prevalence of adjacent segment degeneration after spine surgery: a systematic review and meta-analysis*. Spine, 2013. **38**(7): p. 597-608.
24. Hoogland, T., et al., *Endoscopic transforaminal discectomy for recurrent lumbar disc herniation: a prospective, cohort evaluation of 262 consecutive cases*. Spine, 2008. **33**(9): p. 973-978.
25. Pan, Z., et al., *Efficacy of transforaminal endoscopic spine system (TESSYS) technique in treating lumbar disc herniation*. Medical science monitor: international medical journal of experimental and clinical research, 2016. **22**: p. 530.
26. Chae, K.H., et al., *Strategies for noncontained lumbar disc herniation by an endoscopic approach: transforaminal suprapedicular approach, semi-rigid flexible curved probe, and 3-dimensional reconstruction CT with discogram*. Journal of Korean Neurosurgical Society, 2009. **46**(4): p. 312-316.

Abbreviations:

LDH = Lumbar disc herniation

TPELD = Transforaminal percutaneous endoscopic lumbar discectomy

TESS = Transforaminal endoscopic spine surgery

PLED = Percutaneous endoscopic lumbar discectomy

VAS = Visual analog scale

ODI = Oswestry disability index