



AN UNUSUAL PRESENTATION OF A CASE OF PULMONARY EMBOLISM WITH NORMAL D-DIMER LEVEL

*Dr. Prakash Shrestha, Dr. Hua Wei hua and Prof. Xiao Wei

Pulmonary and Critical Care department, Jingzhou number 1 people's hospital, Jingzhou, Hubei, PR. China.

ABSTRACT

Pulmonary embolus can be life threatening, but is often treatable if recognized early. Unfortunately, the clinical presentation of PE is often variable and misleading. The D- dimer assay has recently come into favor as a method to exclude PE; however, this test has an acceptable safety margin only in low-risk populations. This is the report of a 73-year-old woman with over 3 days of radiating chest pain and intermittent dyspnea. Although enzyme-linked immunosorbent assay (ELISA) D-dimer assays were normal on the initial and subsequent hospital admission with increased creatinine phosphokinase and Troponin positive, Pulmonary embolism (PE) was diagnosed by computed tomography pulmonary angiography scan on the second visit having the features of CAD. This report highlights the risk of misdiagnosing PE if relying solely on ELISA D-dimer for exclusion. This report documents the presentation of PE despite of having unremarkable ELISA D-dimer measurements with cardiac enzymes positive and the sole superiority of CTPA in diagnosis of Pulmonary embolism.

Keywords: D- dimer, PE, CTPA, Warfarin

INTRODUCTION

Pulmonary embolism (PE) is a frequent and potentially severe disease. An accurate and rapid diagnosis of PE remains difficult in clinical practice because of non-specific clinical presentation also treatment carries significant potential side effects, so, objective testing is required to establish or exclude the presence of pulmonary embolism. Although pulmonary angiography is being considered as the definitive diagnostic technique or “gold standard” in the diagnosis of acute pulmonary embolism, it suffers from limitation in its use as a result of being relatively expensive, time-consuming and involves radiation and contrast exposure. In recent years, various combinations of non-invasive aids to diagnose, including the assessment of clinical probability, D-dimer testing, end tidal carbon dioxide (PetCO₂), venous compression ultrasonography of the legs and ventilation perfusion lung scanning or CT pulmonary angiogram(CTPA), have been developed and validated to reduce the need for pulmonary angiography. Pulmonary computed tomography angiography (CTPA) has become the preferred method to confirm or exclude PE. It has been shown to have high specificity, sensitivity, and negative predictive value for the diagnosis of acute PE. D-dimer is a fibrin degradation product (FDP), a small protein fragment present in the blood after a blood clot is degraded by fibrinolysis. It is so named because it contains two cross linked D fragments of the fibrinogen protein. D-dimers are not normally present in human blood plasma, except when the coagulation system has been activated, as in the presence of thrombosis or disseminated intravascular coagulation. The D-dimer assay depends on the binding of a monoclonal antibody to a particular epitope on the D-dimer fragment. The binding of the antibody is then measured quantitatively by one of various laboratory methods. D-dimer assays were characterized by having good sensitivity and negative predictive value, but poor specificity because elevated D-dimer may be present due to various causes as liver disease, high rheumatoid factor, inflammation, malignancy, trauma, pregnancy, recent surgery as well as advanced age. The aim of this case study is to show the role of the diagnostic accuracy of D-dimer assay in patients with suspected pulmonary embolism.

Pulmonary embolism (PE) affects over 1 in 1,000 Americans each year and has a mortality rate greater than 15% in the first 3 months after diagnosis. The most common risk factors for pulmonary emboli and deep vein thrombosis (DVT) include prolonged immobility, older age, history of smoking, inherited clotting factors, and post-operative states. Additionally, the use of oral contraceptives (OCP) is understood to introduce an increased risk, often in conjunction with genetic predisposition such as factor V Leiden mutation. Young women without genetic predisposition who are healthy and active are considered to be a low risk population for DVT and PE. We present the unique case of an old woman, who was initially presented as a case of Acute coronary syndrome with increased cardiac biomarkers with normal healthy life style and later turns out to be a case of Pulmonary embolism with the help of CTPA despite of persistent normal D-

dimer assay and unusual presentation.

Case Presentation:

A 73 years old women, who is in menopausal state, a resident of Kunming, China presented to our hospital with history of sudden onset of chest tightness and shortness of breath from last 3 days which was not associated with PND or orthopnea, with MMRC dyspnoea score of grade 1. It used to worsen on exacerbation and relieved after 5-10 minutes of rest. She denies history of fever or cough. There is neither history of prolonged bed rest nor recent surgery. It was associated with sensation of cramping chest tightness radiating to left arm from last 3 days but denies association with inspiration or expiration. There was no history of edema or loss of consciousness. Appetite was normal.

She is a known case of hypertension under tab. Amlodipine 5mg once daily from last 15 years and maintained within target range.

She denies history of smoking or alcohol consumption. She is physically active and there is no recent surgical history. There is no significant past medical or surgical history.

She was treated in local hospital for 2 days considering the cardiac cause and underwent Coronary angiography having raised CPK total and Troponin I positive, which turns out to be normal but the symptoms were not subsided, hence, she was referred to our hospital for further needful.

DISCUSSION

After arriving to our hospital ER, She was initially examined where her blood pressure was 120/70mmhg, PR: 63bpm and regular, normal chest x-ray with ECG showing normal sinus rhythm shown in figure 1. Although ECG was normal and ABG within normal range, D-dimer and FDP as well as Fibrinogen level were assessed multiple times and found to be within normal limit. Echo cardiography was not significant except mild LVH. After having no evidence of frank cardiac cause and having the evidence of normal Coronary angiography, she was transferred to pulmonary department and reassessed. Having ruled out all possible causes, despite of having low probability modified Wells score and Revised Geneva score. CTPA was considered as a diagnosis of exclusion, hence, CTPA was performed which turns out to have Right sided pulmonary embolism showed down in Figure 2, 3&4. Prior to our hospital D- dimer was performed by ELISA thrice and in our hospital it was performed thrice and all reports were within normal range. She was immediately started with LMWH and overlapped with warfarin. All the possible causes of PE were ruled out including USG Doppler of all limbs, protein C, protein S, Factor V, Antiphospholipid antibody and all of these reports turns out to be normal. Since, there was the evidence of right sided pulmonary embolism, She was maintained with warfarin 2 mg with INR on therapeutic range. She responded well to the treatment and

gradually improved. After 5 days of hospital treatment it was easier for her to walk and clinically comfortable. After assessing her all vitals and lab parameters, She was discharged on warfarin on the 7th day, however, the exact cause of pulmonary embolism was not witnessed despite of all the examinations. So, she was planned to continue the anticoagulant (Warfarin) for 3 months under therapeutic range and follow up after 3 months with repeat CTPA film. After 3 months, CTPA was performed and found to have normal pulmonary vessels. She is planned to continue with warfarin therapy. Since, there is no any positive evidence and patient has been improved clinically and symptomatically having normal lifestyle as before with normal CTPA after 3 months, She is planned to continue warfarin for total of 6 months. She is advised to get follow up after the completion of 6 months of anticoagulation therapy with repeat CTPA film to plan further treatment whether to continue warfarin or not.

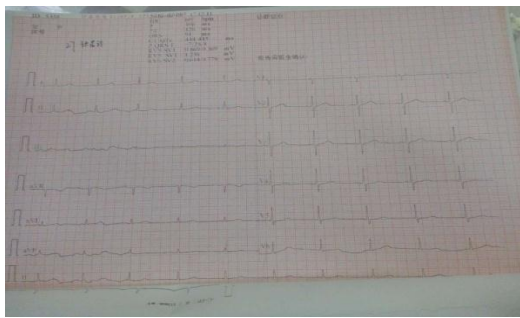


Figure 1: ECG during admission

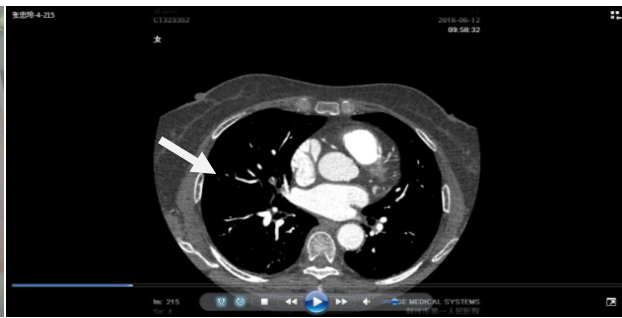

Figure 2: Right sided Pulmonary embolism during admission

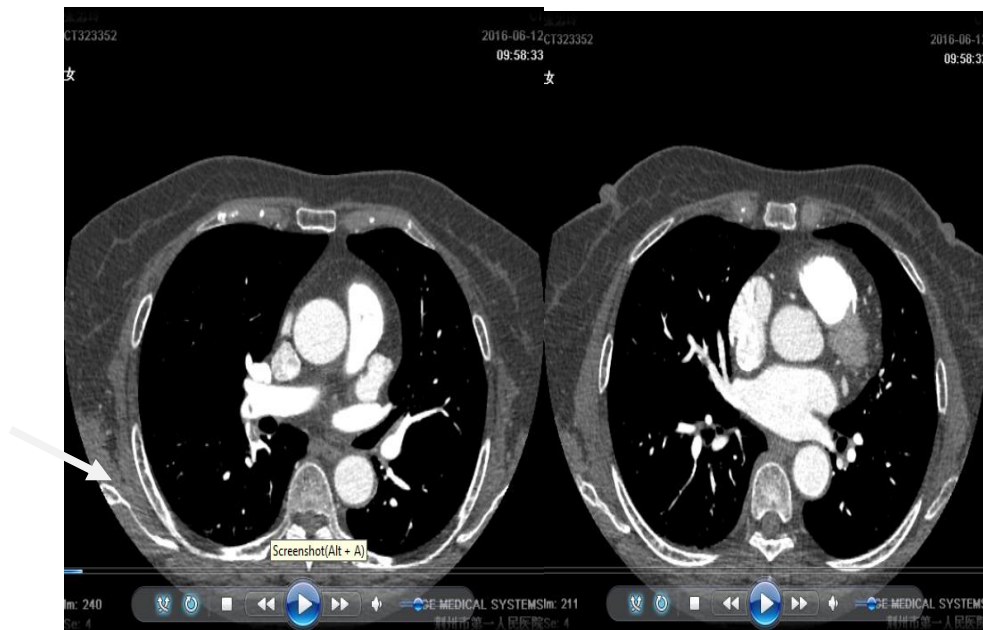


Figure 3&4: CTPA showing right sided Pulmonary embolism

CONCLUSION

This is a very interesting and challenging case, where She was initially presented as a case of chest tightness of cardiac origin as a feature CAD with raised CPKMB and Troponin I positive, however, it turns out to be Pulmonary embolism. This case turns out to be a case of pulmonary embolism where Wells and Revised Geneva score was against it including interestingly normal ECG as well as no evidence of Pulmonary embolism signs in ECHO. Since, we mostly believe D-dimer assay to exclude PE, but in this case, The D-dimer level was in normal range despite of repeated examination in different hospital, whereas, there was evidence of right sided pulmonary embolism with the help of CTPA. The cause of PE in this case was unknown with all possible measures including low Wells criteria and Geneva Score. So, She underwent for coronary angiography which appeared normal and PE was diagnosed as a case of exclusion. Hence, it is worthy to perform CTPA despite negative D-dimer assay, depending on the clinical scenario. This also highlights the increase cardiac markers (troponin and CPK) may be associated with Pulmonary embolism. This case showed us that Pulmonary embolism may present in any unusual scenario for which clinical judgement plays the vital role to save the patients life.

REFERENCES

1. Crawford, F., Andras, A., Welch, K., Sheares, K., Keeling, D., & Chappell, F. M. (2016). D-dimer test for excluding the diagnosis of pulmonary embolism. D-dimer test for excluding the diagnosis of pulmonary embolism. doi:10.1002/14651858.CD010864.pub2
2. Dunn, K. L., Wolf, J. P., Dorfman, D. M., Fitzpatrick, P., Baker, J. L., & Goldhaber, J. L. (2002). Normal d-dimer levels in emergency department patients suspected of acute pulmonary embolism. Normal d-dimer levels in emergency department patients suspected of acute pulmonary embolism, 40. doi:10.1016/S0735-1097(02)02172-1
3. Flores, J., García de, J. T., Galipienzo, J., García-Avello, A., Pérez-Rodríguez, E., Tortuero, J. I., & Álvarez, C. (2015). D-dimer testing to select patients with a first unprovoked venous thromboembolism who can stop anticoagulant therapy: a cohort study. D-dimer testing to select patients with a first unprovoked venous thromboembolism who can stop anticoagulant therapy: a cohort study. doi:10.1007/s11739-015-1306-5. Epub 2015 Sep 7
4. Huckins, D. S., Price, L. L., & Gilley, K. (2012). Utilization and yield of chest computed tomographic angiography associated with low positive D-dimer levels. Utilization and yield of chest computed tomographic angiography associated with low positive D-dimer levels. doi:10.1016/j.jemermed.2011.05.036
5. Jarrea, T., S Hann, E., Rodriguez, F. H., Romero, J., Martinez, J., & Lopez, F. A. (2007). Massive Pulmonary Embolism: A Case Report and Review of Literature. Massive Pulmonary Embolism: A Case Report and Review of Literature, 160(July/August 2008 189). Retrieved from docplayer.net/33214467

6. KATHERINE, R. M., CHARLES, B., & SHERMAN, M. D. (2014). An Unusual Case of Pulmonary Embolism in a Young Healthy Female Competitive Rower. An Unusual Case of Pulmonary Embolism in a Young Healthy Female Competitive Rower.
7. KENNETH, T., & MOON. (2008). d-Dimer Test: A Normal Result Does Not Always Rule Out Pulmonary Embolism. d-Dimer Test: A Normal Result Does Not Always Rule Out Pulmonary Embolism. Retrieved from Chest. October 2008;134(4):789–793
8. Kutinsky, I., Blakley, S., & Roche, V. (1999). Normal D-dimer levels in patients with pulmonary embolism. Normal D-dimer levels in patients with pulmonary embolism. Retrieved from Arch Intern Med. 1999 Jul 26;159(14):1569-72
9. Marc, B. E., Marc, D., & Shu, C. B. (2007). Pulmonary Embolism Despite Negative ELISA D-Dimer: A Case Report. Pulmonary Embolism Despite Negative ELISA D-Dimer: A Case Report. Retrieved from <http://dx.doi.org/10.1016/j.jemermed.2007.11.028>
10. Van der Pol, L. M., Mairuhu, A. T., Tromeur, C., Couturaud, F., Huisman, M. V., & Klok, F. A. (2017). Use of clinical prediction rules and D-dimer tests in the diagnostic management of pregnant patients with suspected acute pulmonary embolism. Use of clinical prediction rules and D-dimer tests in the diagnostic management of pregnant patients with suspected acute pulmonary embolism. doi:10.1016/j.blre.2016.09.003
11. Yan, Z., Ip, I. K., Raja, A. S., Gupta, A., Kosowsky, J. M., & Khorasani, R. (2016). Yield of CT Pulmonary Angiography in the Emergency Department When Providers Override Evidence-based Clinical Decision Support. Yield of CT Pulmonary Angiography in the Emergency Department When Providers Override Evidence-based Clinical Decision Support. doi:10.1148/radiol.2016151985. Epub 2016 Sep 30