



**APPLICATION OF FLEXIBLE URETEROSCOPE FOR SIMULTANEOUS
TREATMENT OF RENAL CALCULI AND CHYLE PARAPELVIC CYST**

Dr. Ashok Raj

*Department of Urology, Affiliated Hospital of Xuzhou Medical College, 99 West Huaihai Road, Xuzhou 221002
China*

ABSTRACT

We present a case of symptomatic renal calculi and unroofing of parapelvic chyle cyst with holmium laser in a 49yrs female. At 6 months follow-up, the patient remains symptom-free.

INTRODUCTION

In a department of urology, parapelvic renal cyst with concomitant calculi is rare to encounter disease. The majority of a cyst and small calculi are not detected unless the symptom appears. Only symptomatic candidate required intervention. In this, both condition patient has flank pain, obstruction of urine outlet, hematuria common in renal calculi and rare in a cyst.

Today's reaching pelvis calculi via a natural route and achieving a high successes rate with lower morbidity have led FUS to become a commonly used important treatment modality.

Meanwhile, with advancement in a newer auxiliary device, such as urethral access sheath, holmium laser fiber, dormia basket, guide wire, and highly experienced surgeon, higher successes rates have achieved with FUS management of renal kidney problem like as, renal calculi and parapelvic cyst.

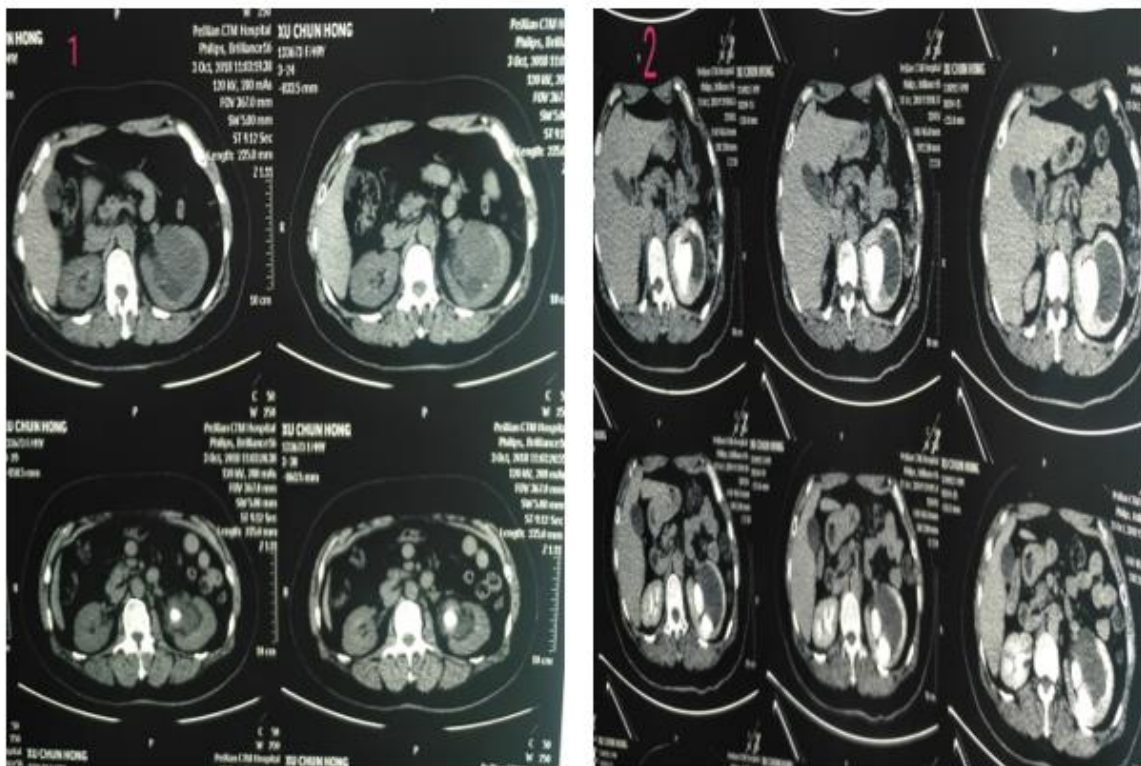
Case report presentation:

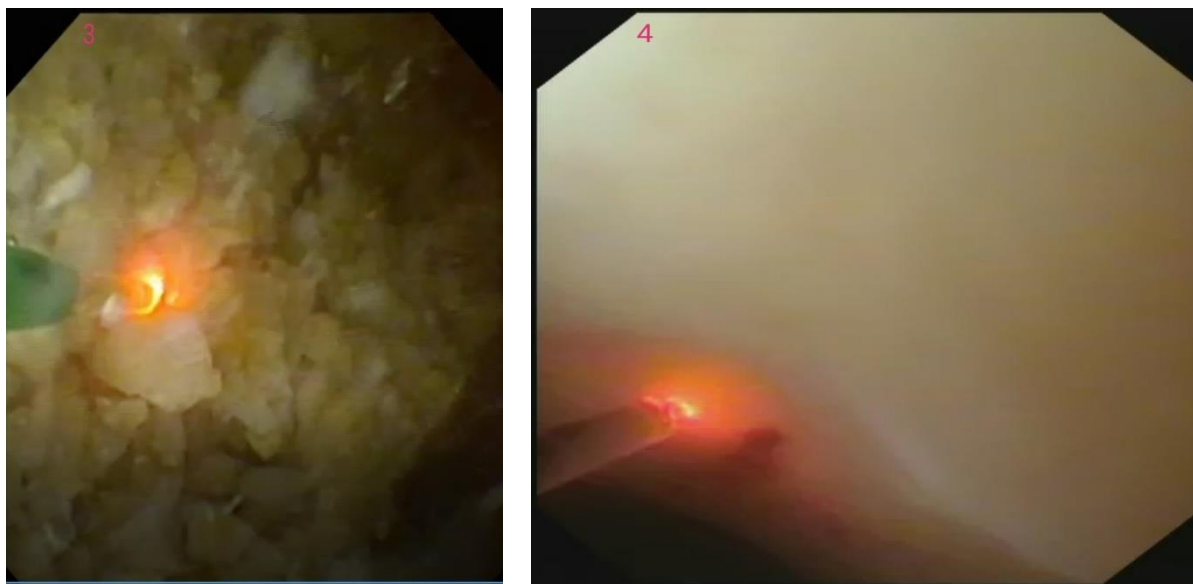
A 49 yrs female presented to our outpatient department with chief complain of plank pain and hematuria.

Investigation:

Lab exam blood and serum test were in normal limits. urinalysis show hematuria ++ and pyuria+. USG of the abdomen reveals renal calculi and parapelvic renal cyst. CT of the abdomen reveals renal calculi 10*12mm and cyst 5.6*4.5 cm. CTU reveal no communication between the calyceal system.

After proper counseling patient was a plan for elective flexible ureteroscope stone fragment and unroofing of a cyst. stone was reached and fragment





CT scan of the patient shown in figure1. CTU of the patient shown in figure 2. Fragments of stone with laser fiber shown figure3. The laser fiber is pointing cysts shown in figure 4.

Treatments:

Under general anesthesia patient was placed in lithotomy position. Urinary bladder was entered with semi-rigid ureteroscope. The guide wire was placed in left ureter. Urethral access sheath was placed over guide-wire into ureter up to pelvis.

After then, FURS was introduced through the ureteral access sheath. the stone was reached and fragment with the laser fiber until the clinically unimportant residual fragment is left[fig2]. Then, parapelvic chyle cyst was found and unroofed with laser fiber[figure3]. after unroofing flux of milky white fluid was released and DJ stent was placed

Follow-up and outcome:

The patient was followup for 3 months. DJ stent was removed after 4 weeks and chyle test was done twice on 2 weeks and 4 weeks was negative. The postoperative period was uneventful.

DISCUSSION

The incident of renal cyst is about 5% and their incident increase with age. despite of their prevalence only 8% become symptomatic and need surgical intervention. In this case, the patient was 49 years female. A CT scan of patients showed renal calculi and parapelvic thick contrast-enhancing septa within the cyst, which may explain the condition.

Although laparoscopy and PCNL most frequently performed the procedure for cyst and calculi. For this case size location of cyst and calculi best for FUS and there was no major complication except discomfort due

to double J Stent. As reported that total incidence of complication was in the range of 6.8-16% major complication included intraoperative urethral perforation avulsion, postoperative infection and hematuria .in In recent years advancement of FURS instrument and auxiliary equipment incident recorded low. As a new method holmium laser the penetrated depth is only 0.4 mm, thus it can provide safety of surrounding tissue injury.

While this procedure postoperative complication such as scarring of the renal pelvis, stasis of urine in an unroofed cyst, recurrent infection, stone formation, and hemorrhage can be avoided. All above complication can manage by placing DJ stent in an unroofed cyst.

Another study has indicated that the FURS combination with the holmium laser can be used to treat the patient with coagulation dysfunction.

Furthermore, a previous study has reported that the furs laser lithotripsy provides an excellent result with low postoperative complication.

One most commonly encounters a problem to identify parapelvic cyst. Sometimes it's difficult to locate cyst to overcome this problem. According to wang Z ET methylene, blue injection percutaneous for parapelvic renal cyst with USG guide is the best option to locate cyst [5].

There are few Limitation of this study firstly cannot perform in multiple small cysts and bigger size stone. Secondly, need procedure expertise and well-equipped center.

CONCLUSION

The present shows that FURS is an effective safe, invasive with minor complication modality for simultaneous renal calculi and parapelvic cyst treatment. In the future, the effects of treatment need to do with the prospective study.

REFERENCES

1. Aging and simple cysts of the kidney. [pubmed]
2. A Prospective Comparative Study Between Minimally Invasive Percutaneous Nephrolithotomy in Supine Position and Flexible Ureteroscopy in the Management of Single Large Stone in the Proximal Ureter. [pubmed]
3. Safety and Efficacy of Flexible Ureteroscopy in Combination with Holmium Laser Lithotripsy for the treatment of Bilateral Upper Urinary Tract Calculi. [pubmed]
4. Flexible Ureteroscopy and Laser Lithotripsy for Stones > 2 cm: A Systematic Review and Meta-Analysis. [pubmed]
5. Methylene blue injection via percutaneous renal cyst puncture used in flexible ureteroscope for treatment of parapelvic cysts: A modified method for easily locating cystic wall. [pubmed]
6. Endoscopic Unroofing of Symptomatic Peripelvic Simple Renal Cyst. [pubmed]

7. Treatment of Parapelvic Cyst by Internal Drainage Technology Using Ureteroscope. and Holmium Laser. [pubmed]
8. Ureteroscopic management of asymptomatic and symptomatic simpleparapelvic renal cysts. [pubmed]
9. Treatment of renal parapelvic cysts with a flexible ureteroscope. [pubmed]
10. Ureteroscopic management of asymptomatic and symptomatic simple parapelvic renal cysts. . [pubmed]
11. Flexible Ureteroscopy and Holmium:YAG Laser Lithotripsy for Stone Disease in Patients with Bleeding Diathesis: aSystematic Review of the Literature. [pubmed]