



## **DERMATOLOGIC MANIFESTATIONS OF SUBSTANCE ABUSE**

\*Redhwan Riyadh Haidar Albattal, Yu Ye-Li, Faisal Abdulsalam Jumah Abloushi,  
Rowida A. Albarmaqi, Abdul Malik and Abdul Wasay

*Department of Dermatology and Venereology, Kunming Medical University, The First Affiliated Hospital of  
Kunming Medical University, P. R. China.*

*Kunming Medical University, 1168 West Chunrong Road, Yuhua Avenue, Chenggong District, Kunming 650500,  
Yunnan, P. R. China.*

### **ABSTRACT**

This review article highlights the abuse of Marijuana, Methamphetamine, Heroin, Ecstasy, Cocaine and Anabolic-Androgenic Steroids, and their impact on the health of the addicts, especially the cutaneous manifestation that appears on users, which are the most common signs and symptoms. It aims to clarify to specialists how dangerous illicit drugs are used on the cutaneous and direct their attention to be aware of dealing with the symptoms of that and reaching to the treatment plan to avoid complications.

## INTRODUCTION

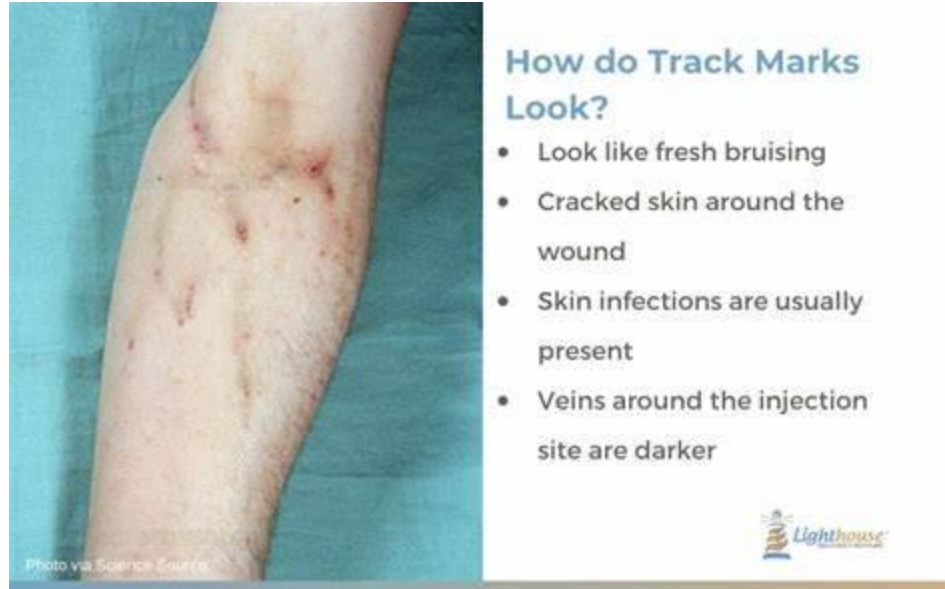Illegal drug use is one of the biggest problems facing among all cultures and developed societies, and despite the efforts made to confront it, it is still increasing. Statistics on delinquency and crime indicate a significant increase in the number of cases of deviant behavior of various kinds between young and old<sup>[1]</sup>. Drug abuse in 2017 amounted to about 271 million people, or 5.5% of the world's population between the ages of 15 and 64, as these figures are 30% higher than the levels in 2009. However, the report attributed this increase in part to the growth of the world's population by 10% in this age group<sup>[2]</sup>. Among the most important complications mainly depending on drug dose injection, the method of delivery, the location of the injection, and the presence of infectious factors. Cutaneous change are the earliest observable results<sup>[3]</sup>.

### **The Most Common Skin Signs of Drug Use:**

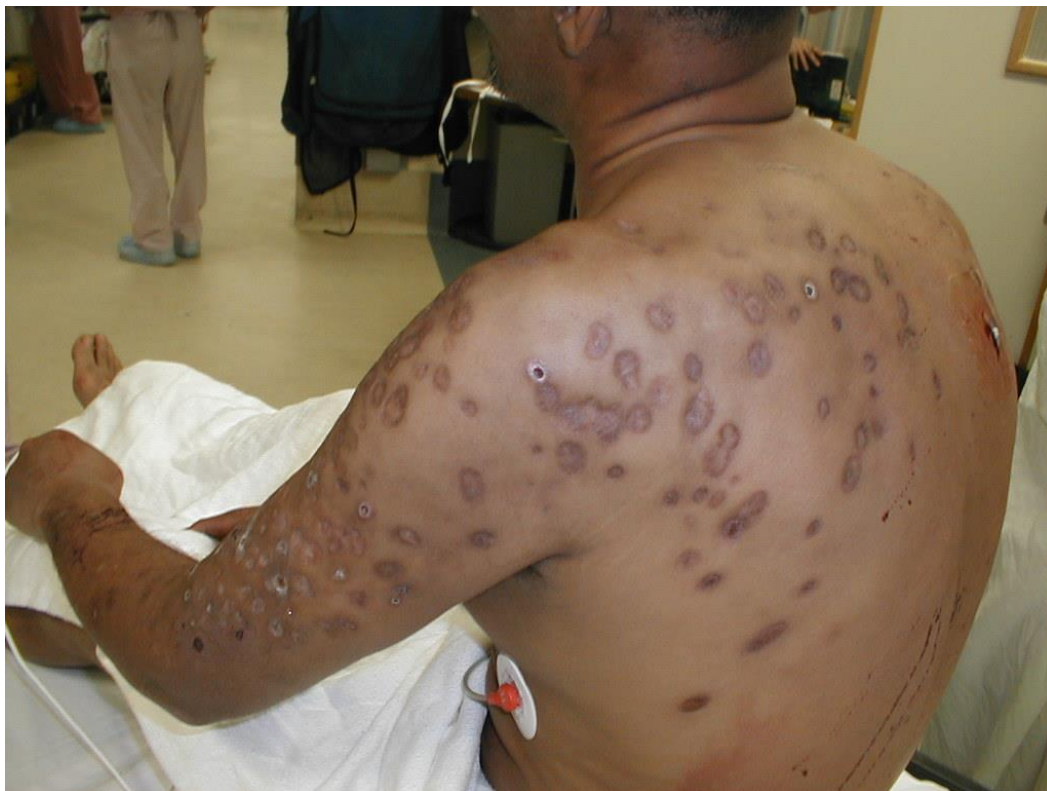#### **Scars Caused by Injecting Drug:**

Often, the most common sign of intravenous drug use is injection marks, it is called "track marks". These signs appear as post-inflammatory hyperpigmentation at the injection location, resulting from destruction and rigidity in the attached veins<sup>[3,4]</sup>. Mostly, signs of injection are in the non-dominant arm, which is easily accessible and often covered with long sleeves clothes<sup>[4]</sup>. In spite of this, there are studies recorded on some drug users who inject it into the clear veins, for example, veins in the neck, as well as in the deep veins like the veins in the feet<sup>[5]</sup>.

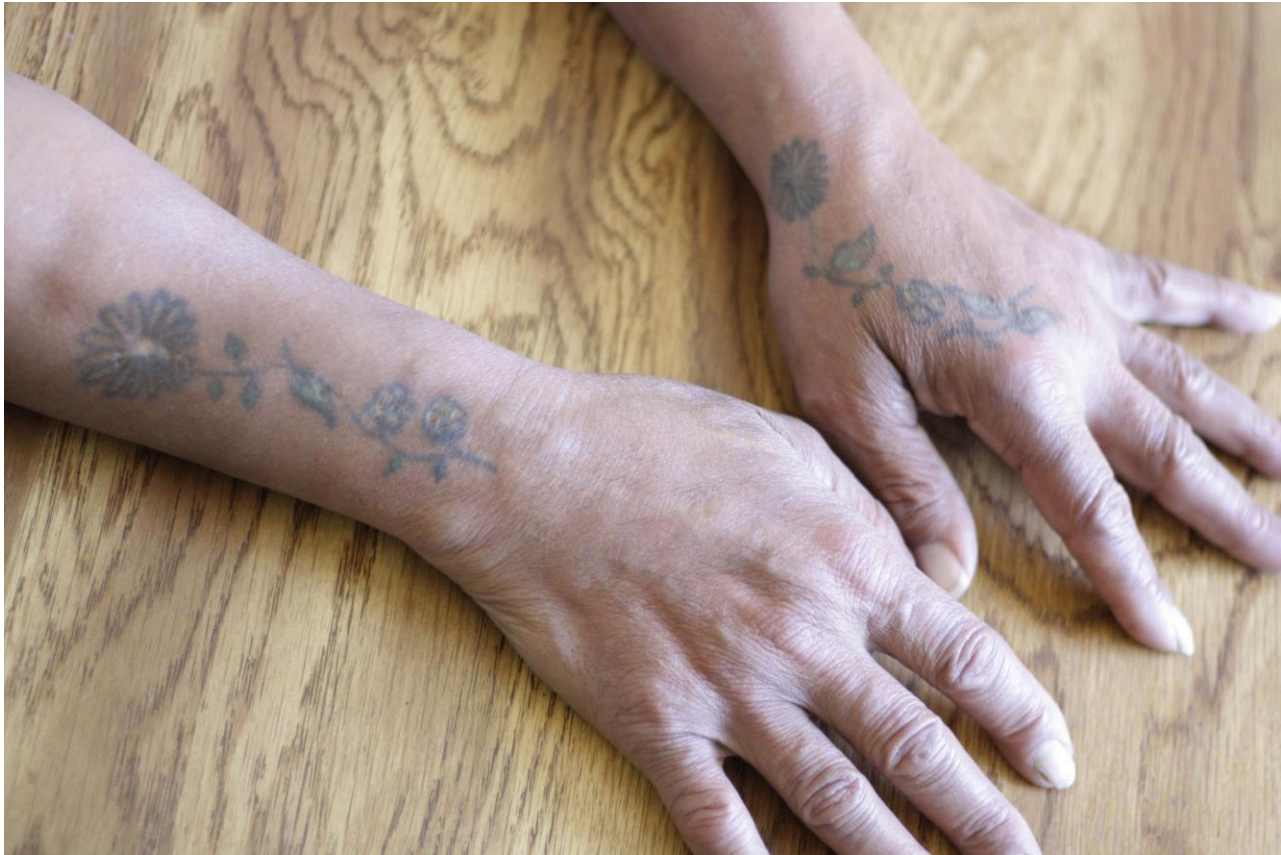



Drug addicts also resort to intradermal, subcutaneous, and sometimes intramuscular drug administration, otherwise called "skin popping" when the veins become firm and unreachable. This approach of drug administration commonly results in deep, circular, punched-out looking atrophic scars; nonetheless, hypertrophic scars and keloids have also been noted. They are often suggestive of scar formation from prior small abscesses, but abscess formation does not surely arise from skin-popping<sup>[3,6]</sup>.



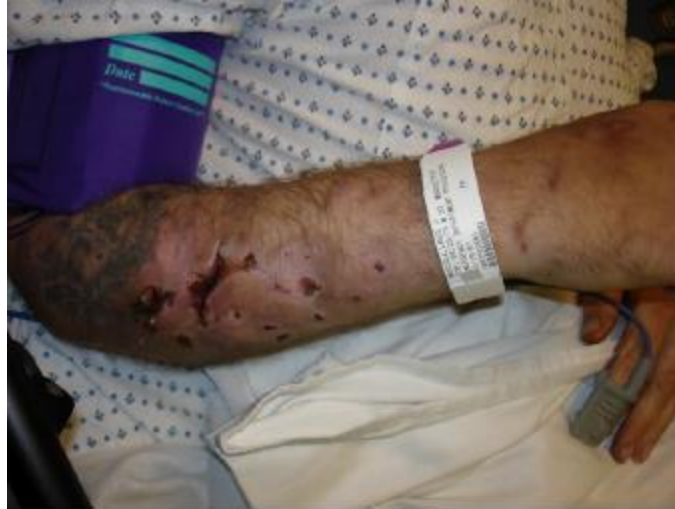Ultimately, the needles used to inject drugs are heated by drug users, which leads to the appearance of marks and accumulation of carbon and some chemical substances at the dermal; therefore, some drug users resort to making commercial tattoos to hide these marks<sup>[4,7]</sup>.



(tattooing to cover the track marks)

### **Infectious Complications of Illegal Drug Abuse:**

One of the most common diseases resulting from injecting drug is the skin and soft tissues infections. It is one of the most common diseases of injecting drug users who visit hospitals including cellulitis and abscesses <sup>[6,8]</sup>. In a community recruitment sample study, Binswanger et al. found that 21% of drug users had abscesses, 3% had cellulitis, and 8% had both<sup>[9]</sup>. There are several risk factors for the progressing of skin and soft tissue infections (SSTI) in injecting drug users, the most important of which is the appearance of the skin-popping<sup>[9]</sup>. The appearance of the skin-popping causes a tissue shock and bacteria entering the skin. It may also insert adulterated materials that can concentrate and irritate the skin locally<sup>[10]</sup>. Other risk factors include the use of non-sterile needles and a "speedball" injection, a mixture of cocaine and heroin<sup>[4,12]</sup>. There are also cases in which osteomyelitis and chondroititis may be potential complications of soft tissue infection after drug abuse <sup>[13]</sup>. Other bacterial infections due to intravenous drug use, tetanus infection, botulinum clostridium, mycobacterium tuberculosis, and systemic Staphylococcal scalded skin syndrome caused by Staphylococcus infection have also been reported<sup>[3,14,15]</sup>.

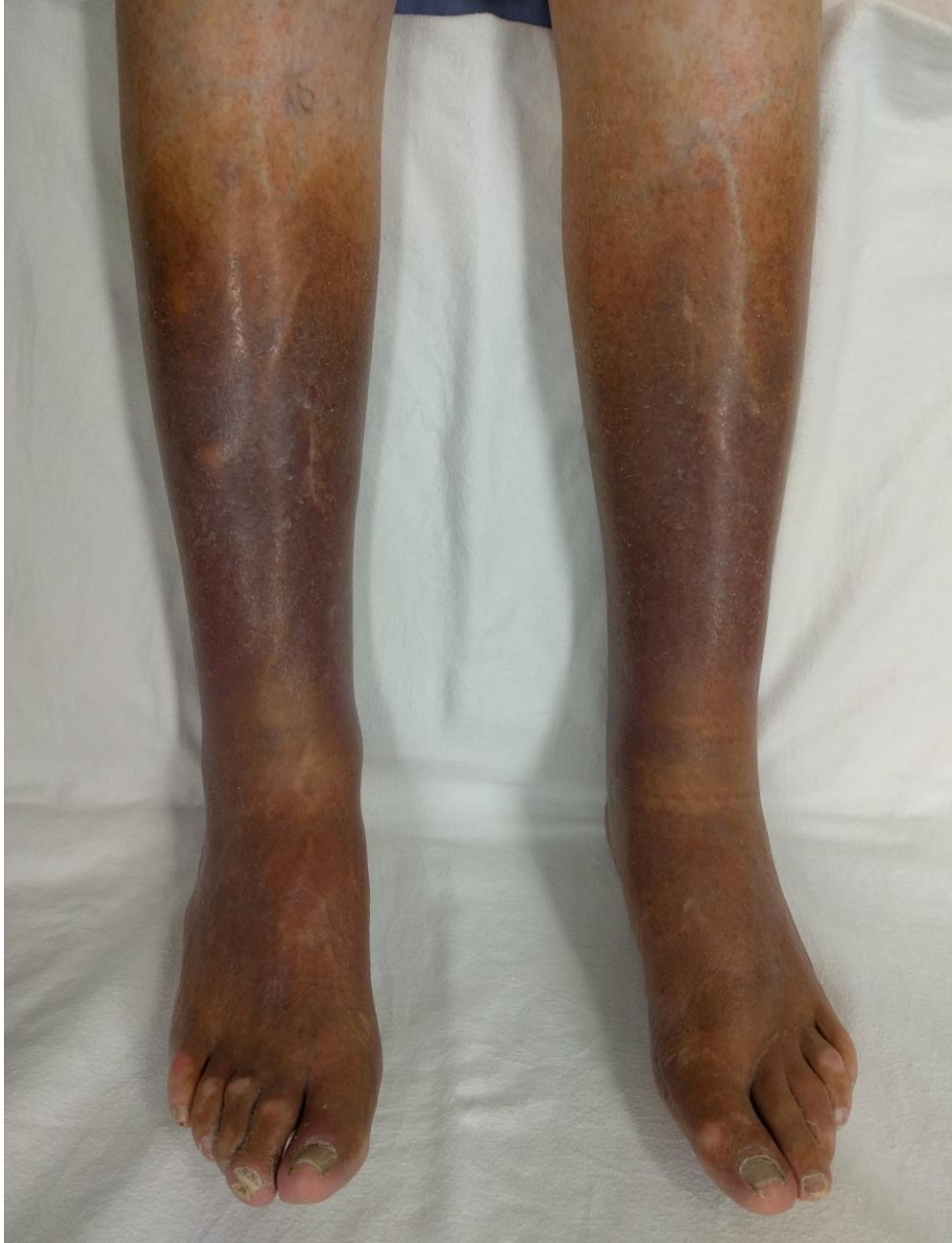

(cellulitis and abscess)

In addition to infectious diseases such as hepatitis B and C and HIV that are transmitted widely through "needle exchange", the study shows that the proportion of drug addicts who suffer from sexually transmitted diseases is about 60% due to sexual intercourse with many sexual partners without wearing a condom<sup>[16,17]</sup>. Include other infections such as infection with herpes simplex 1 and 2, syphilis, gonorrhea, condylomata acuminata infections with *Chlamydia trachomatis*, *Trichomonas vaginalis* and *Gardnerella vaginalis*<sup>[3]</sup>.

### **Blood Vessels Complications:**

A study has found that 88% of injecting drug addicts had chronic venous insufficiency (CVI)<sup>[6]</sup>. Among the most commonly diseases that appeared on injecting drug users related to chronic venous insufficiency are venous damage from repeated needle sticks, thrombophlebitis, and deep venous thrombosis<sup>[18]</sup>.

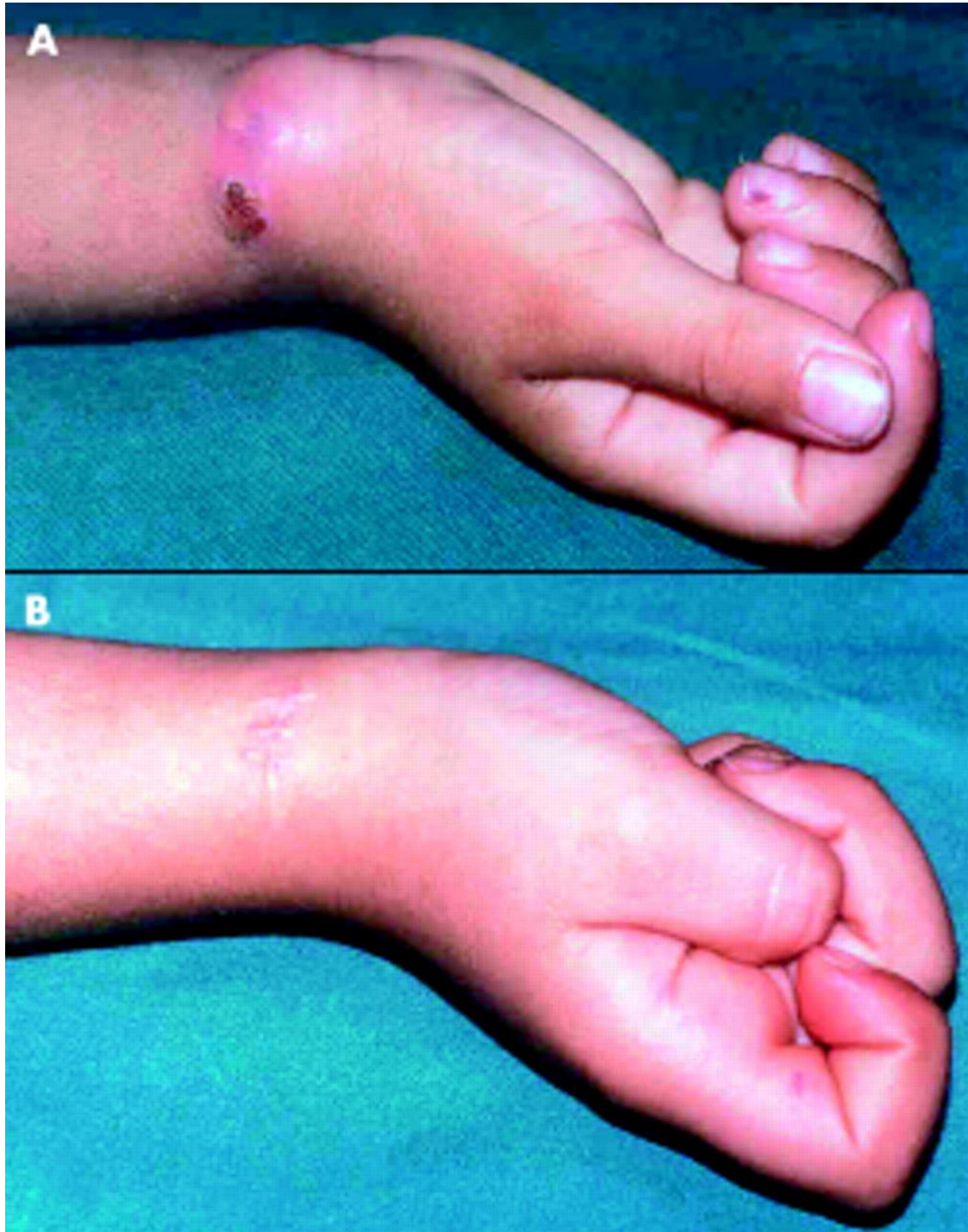


(chronic venous insufficiency)

Intra-arterial injections, severe tissue ischemia, and necrosis could be one of the first signs of injecting drug use, as well as some of the symptoms that appear on injecting drug users, including burning and severe pain, and within a short time, edema begins followed by cyanosis in the injection area<sup>[619,20]</sup>. Various phenomena may lead to vascular injury, cocaine or amphetamines may cause vasoconstrictions. There is chemicals toxicity used in drug substances that may result in chemical endarteritis which may lead to vasospasm and thrombosis.

Infrequently, injecting drug use and vascular damage may lead to pseudoaneurysms and mycotic aneurysms and bacterial infection of blood vessels. It is characterized by pulsing masses in the distribution of

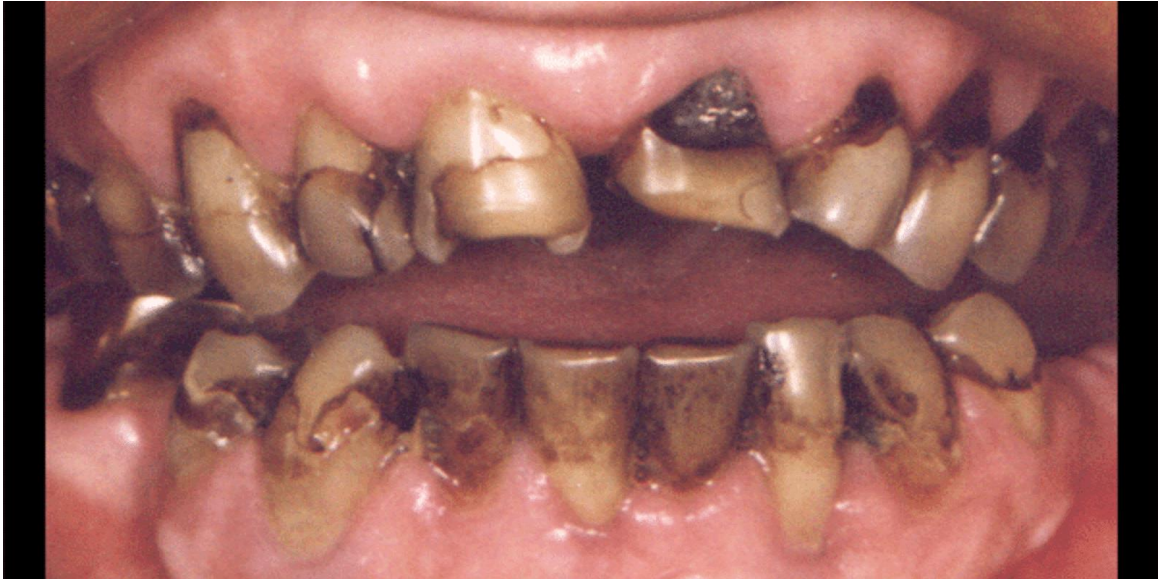the main arteries. The impulsing aneurysm may be confused with abscesses, which can lead to catastrophic results if they are incorrectly incised<sup>[19,21,22]</sup>.



(A) Pseudoaneurysm (B) After treatment of Pseudoaneurysm

### Oral Signs and Symptoms:

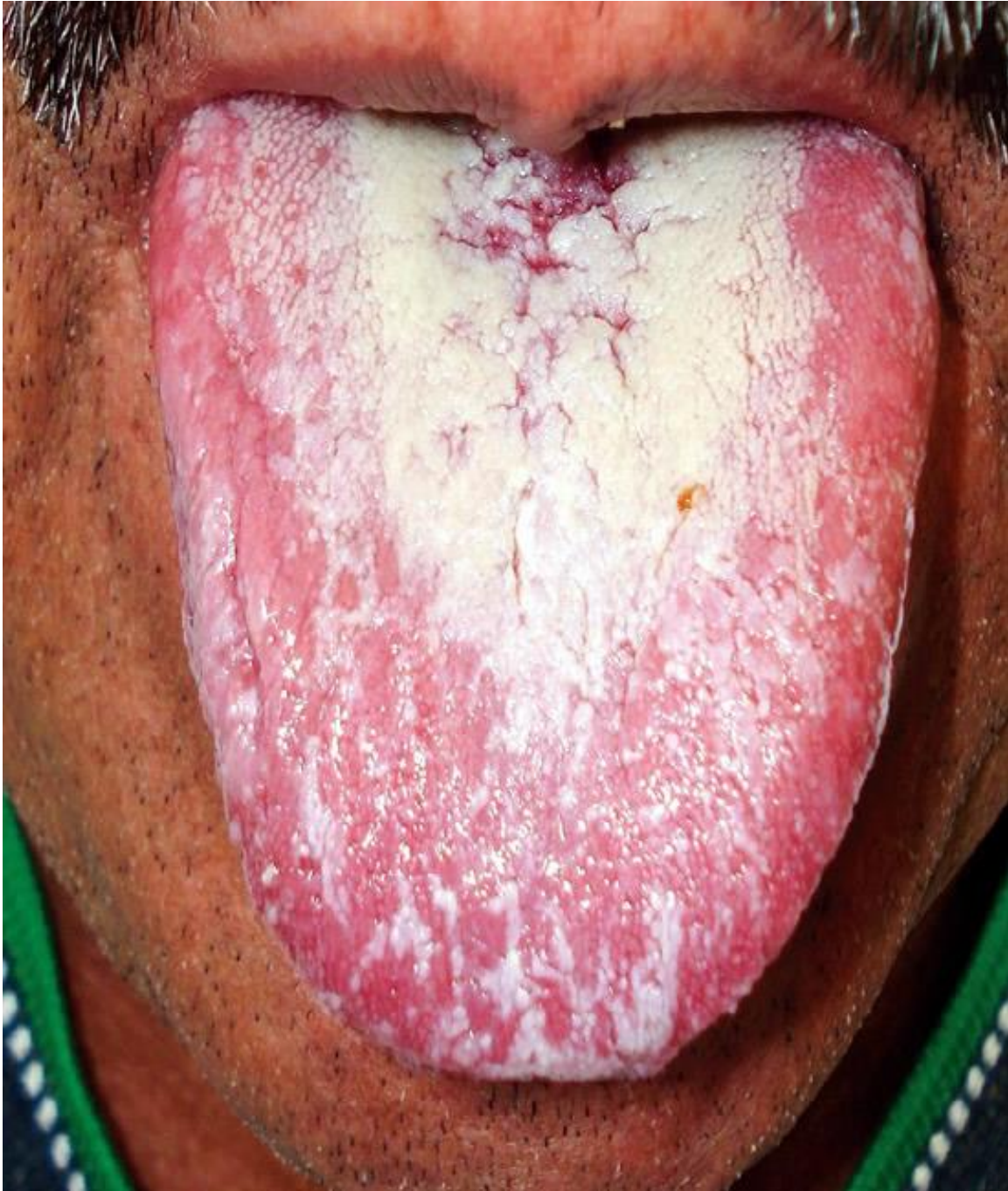
Oral variations and symptoms may appear related to the use of certain types of illegal drugs<sup>[5]</sup>. One of the known effects of methamphetamine use is an oral disease that suffers from severe dental decay that has become known in the media as “meth mouth”. There are some diseases that may appear in users of this substance chronically such as clay occur on the interproximal surfaces of the anterior teeth and the buccal smooth surface of the teeth<sup>[23]</sup>. Patients may suffer from dry mouth, the involuntary or habitual grinding of the teeth and spasm of jaw muscles<sup>[24]</sup>.



(Meth mouth)

Oral fungal infection is one of the most common diseases that appear on drug users<sup>[25]</sup>. A study surveying 13 drug users has found that 12 out of 13 people had positive results with oral candidiasis. Oral candidiasis is the most common cause of mouth infection in drug users. The investigation found that *Candida albicans* is the predominant yeast that colonizes the oral cavity in 47.4% of drug users, followed by 26.3% of *Candida glabrata*, 15.8% of *Candida dubliniensis* and 5.3% of *Candida tropicalis* and *Candida kefyr*<sup>[26]</sup>.





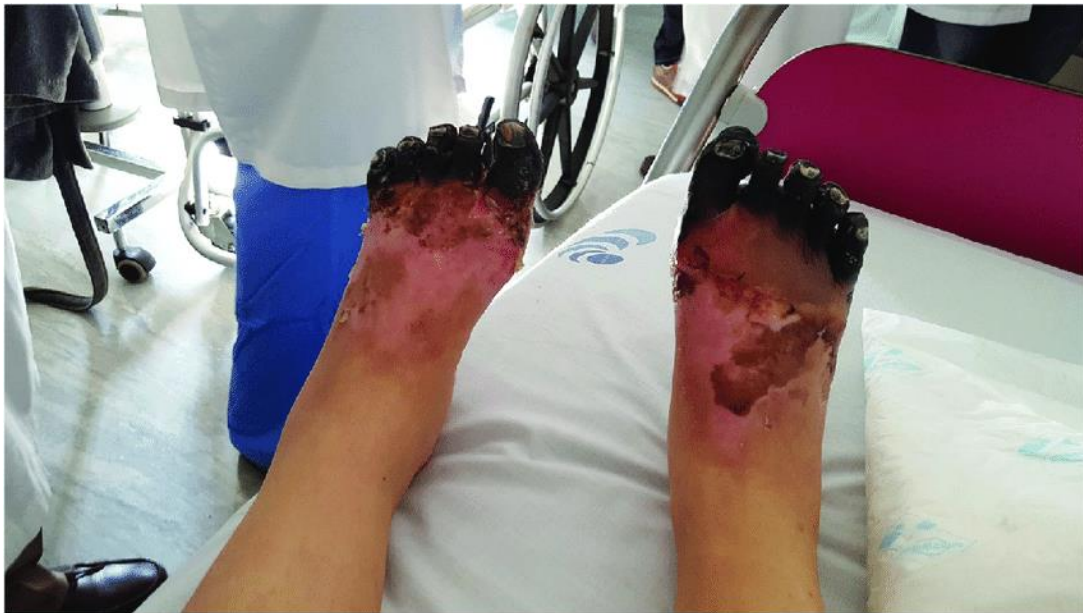(Oral candidiasis)

### **Marijuana Abuse (Cannabis):**

Marijuana abuse (cannabis) is common in the United States. It is commonly smoked as cigarettes made from the stems, leaves and flowering ends of a dried plant (*Cannabis sativa* or *Cannabis indica*). Marijuana is also used as a lawn, i.e. pressurized resin (tar material) for the plant. The certification of marijuana use has spread its products to market so that it can be ingested or vaporized in e-cigarettes. There are also various shapes that can be applied to the skin as dyes, lotions, or sprays [20,27].

The active ingredient of marijuana is a 9-tetrahydro hydrocannabinol (THC) delta. Dronabinol, a synthetic form of the 9-quartile delta hydroquinabenol<sup>[28,29]</sup>. It is being used to relieve nausea and vomiting caused by chemotherapy drugs and to boost appetite in AIDS patients<sup>[30]</sup>.

Among the most common cutaneous manifestations related to marijuana use are premature aging such as losing hair, gray hair color and periorbital dark circles. Chronic marijuana abuse can lead to arteritis that presents often in the lower limbs as peripheral necrosis. It is a type of thromboangiitis obliterans<sup>[31]</sup>. Some studies proved it is caused by the effects of vasoconstriction of delta-9 tetrahydrocannabinol and / or pollutant. Other symptoms such as digital necrosis and Raynaud's phenomenon may appear, followed by advanced symptoms of the disease, ulcers and gangrene. The treatment plan for this disease is to stop using marijuana and also start taking low dose of aspirin and iloprost for severe cases. The patients can fully recover from symptoms related to vasculitis <sup>[31,32]</sup>.



(peripheral necrosis)

A study published in America showed that cannabidiol, which is responsible for the narcotic effect on the Cannabis sativa, might have a positive effect on the skin. The study added that "cannabidiol is able to be a promising active substance in treating severe cases of acne" due to its ability to slow the formation of sebum (which accumulates inside the sebaceous glands and causes the appearance of boils and acne) and its effect on reducing inflammation and irritations <sup>[33,34]</sup>.

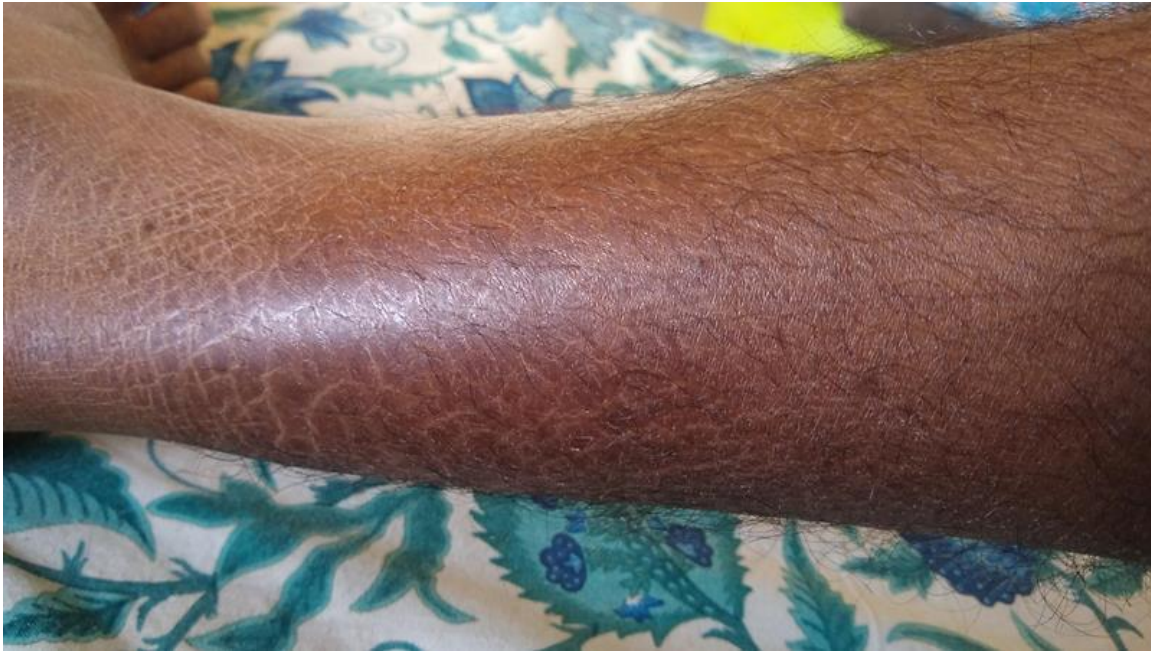### **Methamphetamine (meth) Abuse:**

It is an anesthetic substance that is derived from the stimulant amphetamines of the nervous system, and it is manufactured in laboratory from very dangerous chemical components without medical supervision<sup>[35]</sup>. Methamphetamine causes an increase in the production of nerve hormones, such as dopamine, which are responsible for feeling euphoria and increase activity and movement<sup>[36]</sup>. This is the

result of the acceleration of neurological messages emanating from the brain to all body systems<sup>[36,37]</sup>.

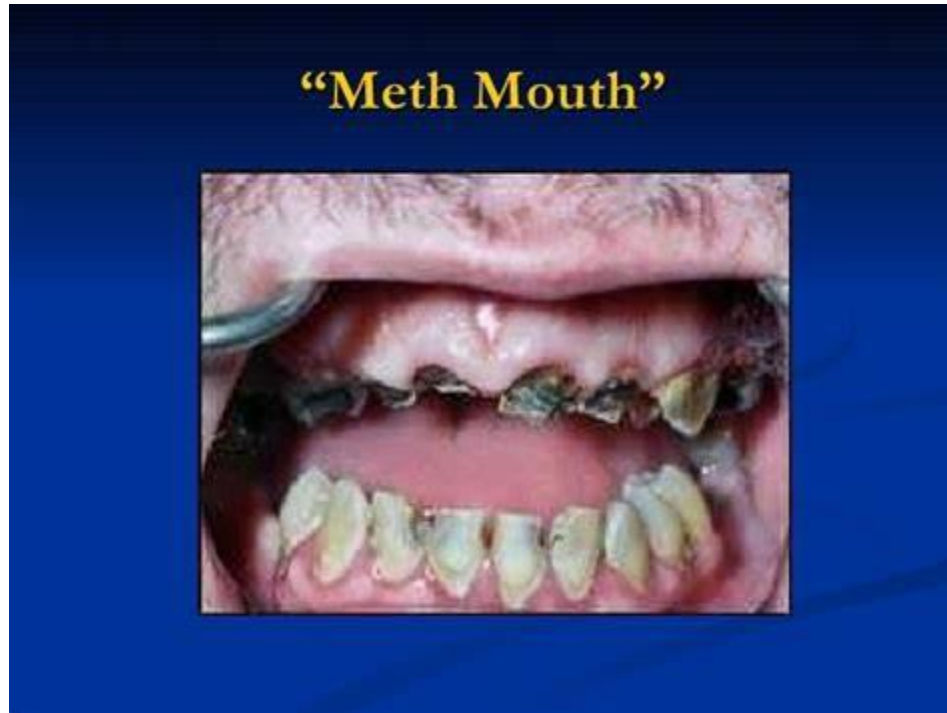
Common cutaneous signs and symptoms include dry skin (xerosis).Meth constricts the blood vessels which may lead to a decrease in blood flow to the skin, pimples or small red spots.

People often pick at them, further, formication could be the side effect of meth abuse that may lead to skin itching and picking which is may appear ulcers in the skin<sup>[4]</sup>.



(xerosis)

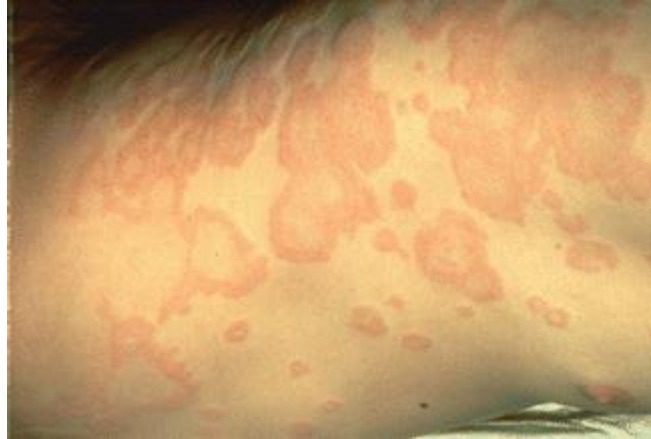Oral diseases with severe dental decay and loss are one of the most common symptoms that may appear on users of methamphetamine called "mouth meth". The main cause of "mouth meth" is unknown, but there are secondary causes that may be the cause of these diseases which are vasoconstriction as well as poor oral hygiene and malnutrition with increased intake of sweetened drinks in an attempt to relieve dry mouth<sup>[38,39]</sup>. Caries may occur in other types of drugs use, but in methamphetamine, it is different.



### **Heroin Abuse:**

It is a white powder with a bitter after taste that sits on the list of highly addictive substances, which can end a person's life in just a few minutes. Heroin is often sold in the form of a powder that has a gray or slightly brownish color, as a result of mixing it with many other compounds such as sugar, starch and others<sup>[40]</sup>. Heroin is the common name for a chemical compound called Diacetylmorphine that is derivative from morphine. The heroin journey begins in the body with the beginning of abuse, whether by smelling, injecting or smoking, and reaches the brain through blood. Then it adheres to the receptors and central neurotransmitters in the body, which are responsible for feeling pain, causing a change in the hormones of dopamine and noradrenaline, and this effect results in a high mood, and a lack of pain<sup>[29,41]</sup>.

The symptoms of heroin use are accompanied by redness of the skin, and persistent itching (chronic pruritus) and this is clearly shown by drug users. 4% of heroin users suffer from urticaria that may last for several days, mainly in the face and genital area. There are three reported cases of heroin addicts who developed cutaneous necrotizing lesions at the sites of intravenous injections<sup>[4,42]</sup>. Three cases are reported with ulcerating nodules resulting from subcutaneous injection of heroin. There is a case reported of ulcers in penis after injecting heroin into the dorsal vein of the penis, and necrotizing cellulitis of the scrotum after injection into the left femoral artery<sup>[43,44,45]</sup>. There are other skin manifestations that have been described with heroin addicts such as toxic epidermal necrolysis, acanthosis nigricans, fixed drug eruptions and necrolytic migratory erythema<sup>[42]</sup>.

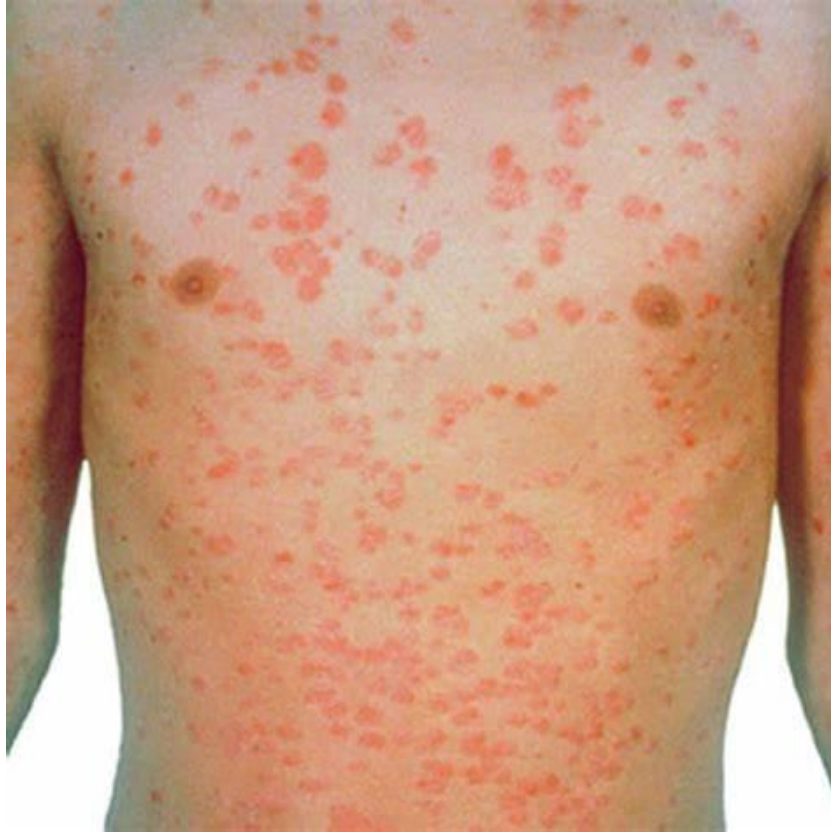

(urticaria)

### **Ecstasy Abuse:**

This drug is one of the stimulant drugs and it is one of the derivatives of amphetamines whose precise scientific name is the drug Ethylene Dioxin Math Amphetamine. This drug is made from the complex stimulant materials chemical composition "ADMA" manufactured in Germany and whose composition was discovered in the year 1918 AD and manufactured in late 1970s AD<sup>[37,46]</sup>. It is an exciting drug for feelings of euphoria, relief and feelings of warmth, and it is a drug that is not 100% pure, but to which other additional substances such as caffeine - paracetamol - amphetamine - ketan - diazepam - and ephedrine - veto-bital are added. The drug is usually distributed in tablet form, but it can be in the form of a powder or capsule, usually consumed by swallowing it orally through pills, inhalation, or by injection<sup>[46]</sup>.

There are few skin manifestations that may appear on the skin of Ecstasy users. A case report showed patient with guttate psoriasis after taking ecstasy<sup>[47]</sup>. Also, a study reported of two ecstasy drug users who developed a papular and pustular rash compatible with the XTC induced severe eruption caused<sup>[48]</sup>.



(Guttate Psoriasis)

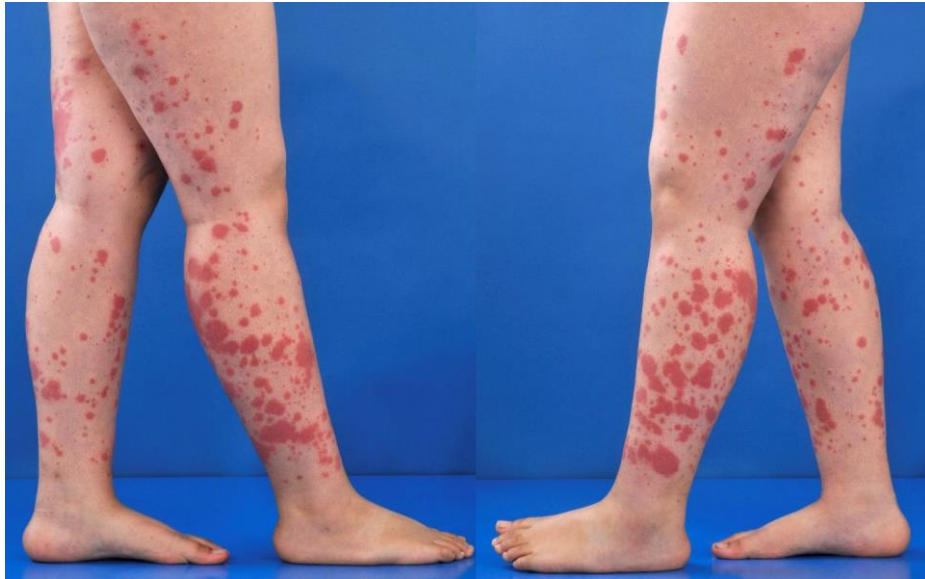### **Cocaine Abuse:**

Cocaine is a powerful stimulant that affects the human central nervous system and is extracted from the leaves of the coca plant. It is sold as white crystalline powder. Cocaine causes severe addiction. It is a severe stimulant of the central nervous system and works to increase the levels of dopamine, a substance in the brain associated with a sense of pleasure and movement. Cocaine has been administered by inhaling cocaine powder through the nose as well as by intravenous, subcutaneous or muscle injection, after dissolving it with water and salt of lemon, sometimes using lemon juice<sup>[29,50]</sup>.

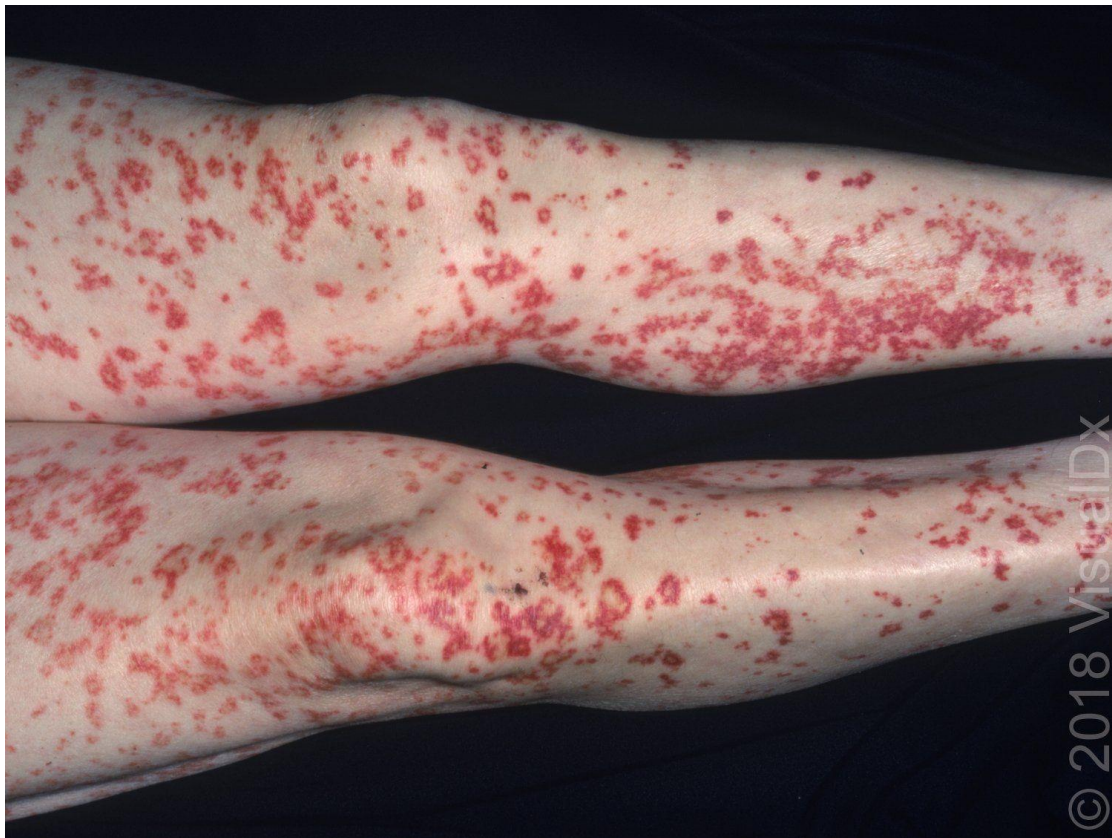Crack is made from cocaine hydrochloride using sodium bicarbonate with water and heated to remove chloride ion. Crack is not pure cocaine, and in the process of making it sodium carbonate remains in the form of salt and limits the purity of hydrochloride, and it is called by this name because the sodium bicarbonate deposits often making a crack when smoking<sup>[29,49,50]</sup>.

Cocaine is associated with many dermatologic manifestations such as Schonlein-Henoch vasculitis, palpable purpura, necrotizing vasculitis, Churg-Strauss vasculitis, Raynaud phenomenon, necrotizing granulomatous vasculitis, midline destructive granulomas, urticarial vasculitis, Stevens-Johnson syndrome, urticarial vasculitis, palatal perforation, pott puffy tumour, dental caries, gingival recession, oral blisters from broken/chipped crack pipes, Pseudovasculitis, cocaine-related bullous disease, chronic skin ulcers,

scleroderma, blackened hyperkeratotic palms “crack hands” from holding the hot crack, subcutaneous fat necrosis of the newborn, acute generalized exanthematous pustulosis and lateral eyebrow loss from hot steam rising from the crack tube<sup>[51,52]</sup>.

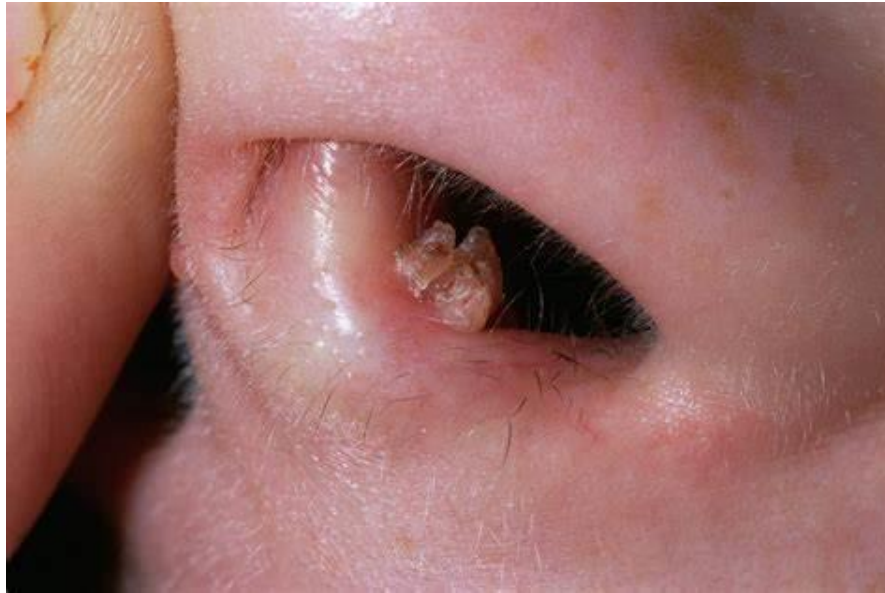

(Henoch Schonlein Purpura vasculitis)



(Palpable purpura)

Nasal verrucae that have been reported in cocaine use is caused by HPV transmission on dollar bills. Dollar bills are used to snort cocaine and pass it from person to another person, which transmits HPV infection<sup>[53]</sup>.



(Nasal verrucae)

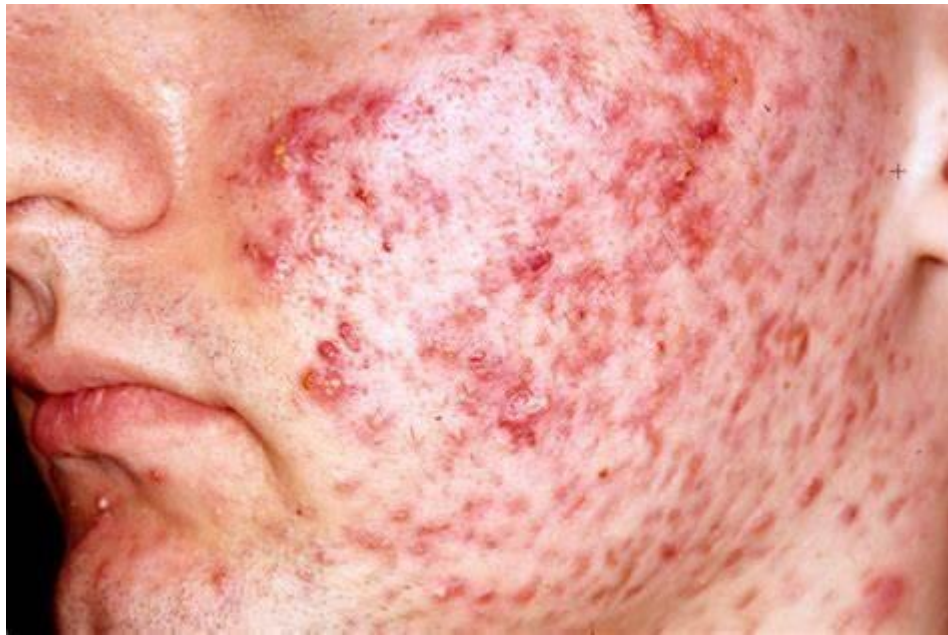### **Anabolic-Androgenic Steroids Abuse:**

Anabolic steroids are a group of natural and synthetic steroid hormones that promote muscle growth and strength. Testosterone is a natural anabolic steroid. A common use of the term refers to artificial male anabolic steroids that mimic the actions of testosterone, the male sex hormone. It stimulates both muscle building and male sexual characteristics. Both synthetic and vitamin steroids have been used in sports, especially bodybuilding to improve performance. They are usually injected but also available orally. It is banned in most sports as performance-enhancing drugs <sup>[54,55]</sup>.

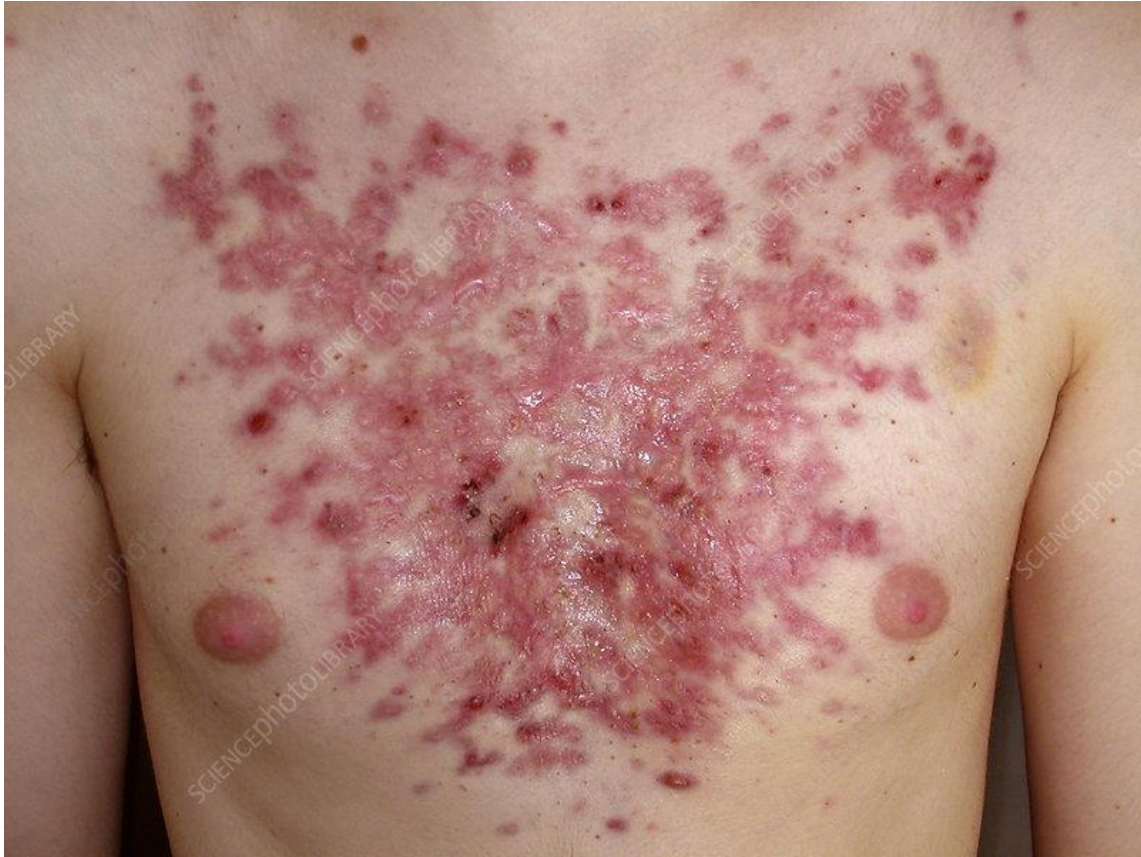There is a group of skin manifestations resulting from the use of AAS. When resorted to without consulting a specialist, there will be clinical signs that will appear on the patients if they continue to take them for a long time. Therefore, dermatologists should be aware of the skin symptoms that appear in athletes due to the abuse of AAS. Broad studies into the instrument of AAS-prompted acne detect the function of the sebaceous organ. AASs actuate the progression of comedones through augmentation and hyper stimulation of the sebaceous gland. Moreover, using of AASs in overdoses leads to an increase in sebum production from the pilosebaceous unit<sup>[56,57]</sup>. Increased sebum production, in association with hyperkeratinization of follicles, eventually activates comedones formation. Studies have demonstrated that adjustments in the sebaceous organ are joined by an increase in breaking down skin surface lipids, the level of cholesterol and free unsaturated fats inside these surface lipids, along with the Propionio bacterium acne populace. Since the exogenous steroid still uses the percentage of surface lipids and P acnes remain elevated <sup>[56,57,58]</sup>.



Acne is one of the most common skin manifestations that may appear because athletes use steroids, which are distributed in various parts of the body such as the face, shoulder, back, and upper chest. If an athlete does not stop using AAS, this may lead to the development of acne vulgaris to acne fulminans, which is ulcerative, painful form of acne, as well as acne conglobata that may appear as comedones, nodules and abscesses. In addition to the occurrence of acne in athletes, steroid use also may induce other cutaneous manifestations because of its stimulation and enlargement of the sebaceous gland<sup>[56,59]</sup>. In addition to the occurrence of acne in athletes, steroid use also may induce other cutaneous manifestations because of its stimulation and enlargement of the sebaceous gland and leads to increased incidence of Alopecia, Epidermoid cysts, seborrheic dermatitis, rosacea and oily hair and skin. A study states that steroid use may lead to secondary infections such as furunculosis and folliculitis due to the increased activity of the sebaceous gland. Furthermore, the misuse of anabolic androgenic steroids may result in an effect on hair growth, including alopecia of the scalp and hirsutism, which appears on the male and female but at a higher rate in the female. Some athletes take steroids to increase muscle mass and strength. The muscle mass expands inconsistently, which leads to the presence of linear striae in different parts of the body, often appearing on the upper part of the body due to the greater muscle mass in the upper part of the body; neck, trunk, shoulders, and upper arms<sup>[57]</sup>.



(Acne Vulgaris)



(Acne conglobata)

## CONCLUSION

Drug use has a strong relationship associated with cutaneous manifestations, not only pathognomic. It can have cutaneous signs. Each drug has a different effect from the other drugs, so some drugs affect the body organs and tissues. Cutaneous stigmata and manifestations are mainly related to the way illegal drugs are used, including intravenous injection, subcutaneous or intradermal injection, intramuscular injection, nasal inhalation, hot suction, etc. The most closely related to skin complications is injection drug use. Cutaneous stigmata is also associated with the type of illegal drug addiction.

Dermatologists deal with drug addicts through reinforcing them to seek immediate medical assistance and quickly join a specialized treatment program in order to avoid the catastrophic effects that the drug leaves on the skin and tissues, and thus granting the ease of treatment and access to recovery.

## REFERENCES

1. World Health Organization. WHO Expert Committee on Drug Dependence – WHO Technical Report Series, No. 915 - Thirty-third Report. Geneva: UN. 2003.

2. World Drug Report 2019 (United Nations publication, Sales No. E.19.XI.8).
3. Fink B, Landthaler M, Hafner C. Skin alterations due to illegal drug abuse. *J Dtsch Dermatol Ges.* 2011;9(8):633-639.
4. Hennings C, Miller J (2013) Illicit drugs: What dermatologists need to know. *J Am Acad Dermatol* 69: 135-142.
5. Liu SW, Lien MH, Fenske NA. The effects of alcohol and drug abuse on the skin. *Clin Dermatol.* 2010;28(4):391-399.
6. Del Giudice P (2004) Cutaneous complications of intravenous drug abuse. *Br J Dermatol* 150: 1-10.
7. Rosen VJ (1985) Cutaneous manifestations of drug abuse by parenteral injections. *Am J Dermatopathol* 7: 79-83.
8. Vollum DI (1970) Skin lesions in drug addicts. *Br Med J* 2: 647-650.
9. Theodorou S, Haber PS. The medical complications of heroin use [J]. *Current Opinion in Psychiatry*, 2005, 18(3): 257-263.
10. Gontijo B, Bittencourt FV, Lourenço LFS (2006) Skin manifestations of illicit drug use. *Anais Brasileiros de Dermatologia* 81: 307-317.
11. Binswanger IA, Kral AH, Bluthenthal RN, Rybold DJ, Edlin BR (2000) High prevalence of abscesses and cellulitis among community-recruited injection drug users in San Francisco. *Clin Infect Dis* 30: 579-581.
12. Murphy EL, DeVita D, Liu H, Vittinghoff E, Leung P, et al. (2001) Risk factors for skin and soft-tissue abscesses among injection drug users: a case-control study. *Clin Infect Dis* 33: 35-40.
13. Ritland D, Butterfield W. Extremity complications of drug abuse [J]. *American Journal of Surgery*, 1973, 126(5): 639-648.
14. Louria DB, Hensle T, Rose J. The major medical complications of heroin addiction [J]. *Annals of Internal Medicine*, 1967, 67(1): 1-22.
15. Galldiks N, Nolden-Hoverath S, Kosinski CM, et al. Rapid geographical clustering of wound botulism in Germany after subcutaneous and intramuscular injection of heroin [J]. *Neurocritical Care*, 2007, 6(1): 30-34.
16. M Fishbein. Methamphetamine use and HIV risk behaviors among heterosexual men--preliminary results from five northern California counties, December 2001-November 2003 [J]. *Morbidity & Mortality Weekly Report*, 2006, 55(10): 273-277.
17. Mansergh G, Purcell DW, Stall R, et al. CDC Consultation on Methamphetamine Use and Sexual Risk Behavior for HIV/STD Infection: Summary and Suggestions [J]. *SAGE Publications*, 2006, 121(2): 127-132.
18. Pieper B, Kirsner RS, Templin TN, Birk TJ (2007) Chronic venous disease and injection drug use. *Arch Intern Med* 167: 1807.
19. Woodburn KR, Murie JA (1996) Vascular complications of injecting drug misuse. *Br J Surg* 83: 1329-1334.
20. Maxwell TM, Olcott C 4th, Blaisdell FW (1972) Vascular complications of drug abuse. *Arch Surg* 105: 875-

882.

21. Cruz JS, Teixeira JF, Costa HM, Braga AR (1999) False aneurysm of an axillary artery in an intravenous drug misuser. *Eur J Surg* 165: 505-506.
22. Georgiadis GS, Bessias NC, Pavlidis PM, Pomoni M, Batakis N, et al. (2007) Infected false aneurysms of the limbs secondary to chronic intravenous drug abuse: analysis of perioperative considerations and operative outcomes. *Surg Today* 37 :837-844.
23. Shaner JW. Caries associated with methamphetamine abuse. *J Mich Dent Assoc* 2002;84:42-7.
24. Pabst A, Castillo-Duque JC, Mayer A, Klinghuber M, Werkmeister R. Meth Mouth-A Growing Epidemic in Dentistry?. *Dent J (Basel)*. 2017;5(4):29. Published 2017 Oct 30.
25. Small CB, Klein RS, Friedland GH, et al. Community Acquired Opportunistic Infections and Defective Cellular Immunity in Heterosexual Drug Abusers and Homosexual Men[J]. *The American Journal of Medicine*, 1983, 74(3):433-441.
26. Hadzic S, Dedica A, Gojkovic Vukelic M, et al. The Effect of Psychoactive Substances (Drugs) on the Presence and Frequency of Oral Candida Species and Candida Dubliniensis[J]. *Materia SocioMedica*, 2013, 25(4):223-225.
27. National Institute on Drug Abuse. Marijuana.
28. Cottencin O, Karila L, Lambert M, Arveiller C, Benyamina A, et al. (2010) Cannabis arteritis: review of the literature. *J Addict Med* 4:191-196.
29. Office of National Drug Control Policy. The price and purity of illicit drugs: 1981 through the second quarter of 2003 (publication number NCJ 207768), national survey on drug use and health. Washington (DC): Executive Office of the President; 2004.
30. Mack A, Joy J. Marijuana as Medicine? The Science Beyond the Controversy. Washington (DC): National Academies Press (US); 2000. 6, MARIJUANA AND CANCER.
31. Noël B, Ruf I, Panizzon RG (2008) Cannabis arteritis. *J Am Acad Dermatol* 58: S65-67.
32. Cazalets C, Laurat E, Cador B, Jan F, Rolland Y, et al. (2003) [Cannabis arteritis: four new cases]. *Rev Med Interne* 24: 127-130.
33. Oláh A, Tóth BI, Borbíró I, Sugawara K, Szöllösi AG, et al. (2014) Cannabidiol exerts sebostatic and antiinflammatory effects on human sebocytes. *J Clin Invest* 124: 3713- 3724.
34. Appendino G, Gibbons S, Giana A, Pagani A, Grassi G, et al. (2008) Antibacterial cannabinoids from *Cannabis sativa*: a structure-activity study. *J Nat Prod* 71: 1427-1430.
35. Volkow ND (2013) Methamphetamine, in National Institutes of Health Research Report Series. National Institute on Drug Abuse.
36. Rusyniak DE. Neurologic manifestations of chronic methamphetamine abuse. *Neurol Clin*. 2011;29(3):641-655. doi:10.1016/j.ncl.2011.05.004
37. National Institute on Drug Abuse. Research report series:methamphetamine abuse and addiction. National Institutes of Health publication number 06-4210. September 2006. Available from: <http://www.drugabuse.gov/sites/default/files/rrmetham.pdf>. Accessed January 31, 2013.

38. Bergstrom KG (2008) Cutaneous clues to drug addiction. *J Drugs Dermatol* 7: 303-305.
39. Brown RE, Morisky DE, Silverstein SJ (2013) Meth mouth severity in response to drug- use patterns and dental access in methamphetamine users. *J Calif Dent Assoc* 41: 421- 428.
40. NIDA. 2020, May 28. What is heroin and how is it used?. Retrieved from <https://www.drugabuse.gov/publications/research-reports/heroin/what-heroin> on 2020, July 5
41. Kreek MJ, Bart G, Lilly C, Laforge KS, Nielsen DA. Pharmacogenetics and human molecular genetics of opiate and cocaine addictions and their treatments. *Pharmacol Rev.* 2005;57:1-26.
42. Young AW Jr, Sweeney EW. Cutaneous clues to heroin addiction. *Am Fam Physician* 1973;7:79-87.
43. Minkin W, Cohen HJ. Dermatologic complications of heroin addiction. *N Engl J Med.* 1967;277(9):473-475. doi:10.1056/NEJM196708312770907
44. Bennet RG, Leyden JJ, Decherd JW. The heroin ulcer: new addition to the differential diagnosis of ulcers of the penis. *Arch Dermatol* 1973;107:121-2.
45. Alguire PC. Necrotizing cellulitis of the scrotum: a new complication of heroin addiction. *Cutis* 1984;43:93-5.
46. Garcia-Romeu A, Kersgaard B, Addy PH. Clinical applications of hallucinogens: A review. *Exp Clin Psychopharmacol.* 2016;24(4):229-268. doi:10.1037/pha0000084
47. Tan B, Foley P. Guttate psoriasis following Ecstasy ingestion. *Aust J Derm* 2004;45:167-9.
48. Wollina U, Kammler H, -J, Hesselbarth N, Mock B, Bosseckert H: Ecstasy Pimples – A New Facial Dermatitis. *Dermatology* 1998;197:171-173.
49. Bernardo Gontijo, Flávia Vasques Bittencourt, Lívia Flávia Sebe Lourenço. Skin manifestations of illicit drug use. *An Bras Dermatol.* 2006;81(4):307-17.
50. US Department of Health and Human Services. Research report series. Cocaine: abuse and addiction. National Institute on Drug Abuse. National Institutes of Health publication number 10-4166, September 2010. Available from: <http://www.drugabuse.gov/sites/default/files/rrcocaine.pdf>. Accessed January 31, 2013.
51. Brewer JD, Meves A, Bostwick JM, Hamacher KL, Pittelkow MR. Cocaine abuse: dermatologic manifestations and therapeutic approaches. *J Am Acad Dermatol.* 2008;59(3):483-487. doi:10.1016/j.jaad.2008.03.040
52. Lu LK, High WA. Acute generalized exanthematous pustulosis caused by illicit street drugs? *Arch Dermatol* 2007;143:430-1.
53. Schuster DS. Snorters' warts. *Arch Dermatol* 1987;123:571.
54. Raiker N, Aouthmany M, Ezra N (2016) Dermatologic Signs and Symptoms of Substance Abuse. *J Clin Exp Dermatol Res* 7: 337.
55. Volkow ND Anabolic Steroids in National Institute on Drug Abuse Research Report Series National Institutes of Health
56. Scott MJ, Scott AM (1992) Effects of anabolic-androgenic steroids on the pilosebaceous unit. *Cutis* 50: 113-

116.

57. Walker J, Adams B (2009) Cutaneous manifestations of anabolicandrogenic steroid use in athletes. *Int J Dermatol* 48: 1044-1048.
58. Merkle T, Landthaler M, Braun-Falco O (1990) Acne conglobata-like exacerbation of acne vulgaris following administration of anabolic steroids and vitamin B complex- containing preparations. *Hautarzt*, 41:280-282.
59. Walker SL, Parry EJ. Acne induced by “Sus” and “Deca”. *Clin Exp Dermatol* 2005; 31: 297–298.