



## **EFFICACY OF ANTI-VASCULAR ENDOTHELIAL GROWTH FACTOR AGENTS IN RETINAL DISORDER FOR BETTER VISUAL ACUITY**

Diwakar chaudhary<sup>\*1, 2</sup>, Hu shuqiong, Long Yuan and Xiong kun

<sup>1</sup>*Yangtze University, 1 Nanhuan Road Jingzhou Hubei 434023, P.R. China*

<sup>2</sup>*Department of Ophthalmology, Aier Eye Hospital, No.38 Changgang Road, Shashi District, Jingzhou City, Hubei Province, P.R. China*

### **ABSTRACT**

To describe the efficacy of intravitreal injection of anti-vascular endothelial growth factor(anti-VEGF) agents for patient with retinal disorders.A case of 35 years old men presented with severe acute vision loss in the right eye. Dilated examination demonstrated cherry red spot with surrounding edema in the macula. Optical coherence tomography showed hyperreflectivity in the middle retinal layer of the macula consistent with maculopathy. Laser therapy was given which shows no improvement to visual outcome. Patient was given anti-VEGF agent, in the first 2-3 follow up no improvement with visual acuity. After receiving anti-VEGF agent five times patient visual acuity was improved.

**Key words:** Anti-VEGF (vascular endothelial growth factor); Retinal Disorder; VA (visual acuity)

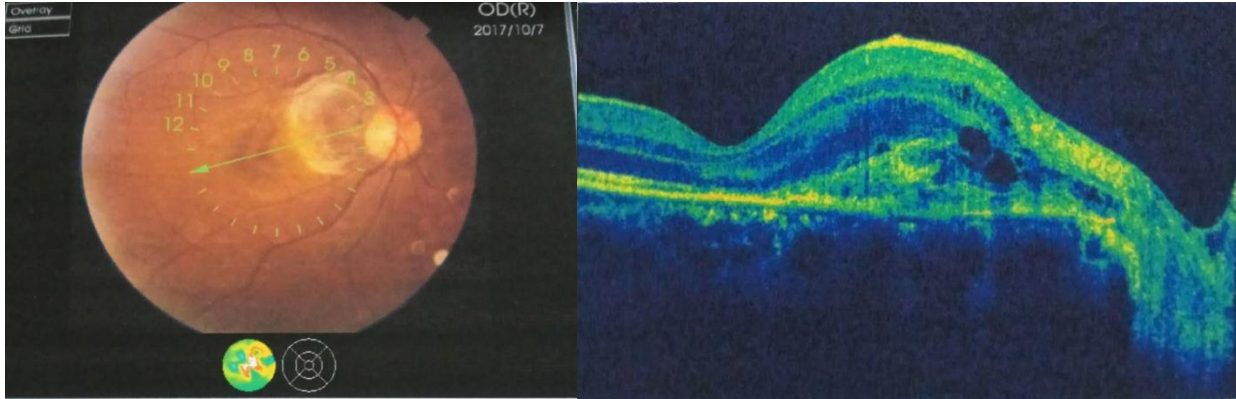
## INTRODUCTION

The most common cause of vision loss in eyes with retinal disorders are retinal vein occlusion (RVO), proliferative diabetic retinopathy and diabetic macular edema(DME), wet age related macular degeneration(AMD), myopic neovascularization and retinopathy of prematurity. The neovascular glaucoma, vitreous hemorrhage and retinal detachment these are the complications of neovascularization which can causes visual impairment[1]. Age related macular degeneration(AMD) is the leading cause of blindness in the elderly [2]. Due to an aging and increasingly obese population the onset of diabetes and subsequent complications is most common in young or middle aged groups, the disease affects patients during their working lives[3]. Visual impairment also cause significant economic burden on a global scale, including costs of treatment, other direct costs associated with vision impairment[4]. Laser photocoagulation and photodynamic therapy(PDT) are the early treatment options for these conditions, it shows poor visual outcomes and risk of adverse effects [5, 6]. Treatment with anti-VEGF has been shown to be efficient not only in maintaining visual acuity but to improve visual outcome for all subtypes of choroidal neovascularization(CNV) secondary to AMD [7].

## CASE REPORT

A case of 35 years old man presented with sudden loss of vision in his right eye. The vision loss occurred after driving. Patient immediately consult with an Ophthalmologist. Patient is known hypertensive under medication (Chinese traditional medicine) since 3 months. Patient was diagnosed with renal stone 2 years back, and renal cyst 1year back, denied for any surgery procedure in his past. He also denied history of trauma. On examination, best corrected visual acuity(VA) was 0.02 on the right and 1.0 on the left. Detailed examination demonstrated a cherry spot with surrounding edema in the macula on the right eye. The left eye was normal. Optical coherence tomography (OCT) showed macular bleeding in the right eye(**figure 1**).The pupil of right eye was dilated, Intraocular pressure was normal. Patient was advised for laser therapy and underwent for the procedure as an out- patient. During his first follow up his visual acuity was not improved. Patient was advised for anti-VEGF therapy and admitted for further investigation all the blood test was performed including complete blood count, serology, prothrombin time, partial thromboplastin time, glycosylated haemoglobin, renal function test, C-reactive protein, lipid profile, urine were within normal limit.

Patient was injected with anti-VEGF and discharged next day. In the first follow up patient VA was not improved and planed for another anti -VEGF injection. All together patients were injected five times with anti-VEGF agents and finally patient VA was improved from 0.02 to 0.3, patient was advised to maintain necessary precautions, informed about risks of disease reactivation in future.



**Figure 1:** OCT showing macular bleeding in the right eye, Hyperreflectivity in the middle retinal layer of macula.

## DISCUSSION

Decreased visual acuity due to macular edema is usually reversible in acute cases of RVO. Whenever the macular edema is resolved after single or repetitive treatments of anti-VEGF agents, visual recovery is satisfactory in many eyes with RVO and macular edema. In some cases with resolved RVO and macular edema showed incomplete visual recovery[8]. Photoreceptors are supplied from Choroidal circulation through the retinal pigment epithelium(RPE) not from the retinal circulation. So it is difficult to speculate if retinal circulatory disturbances caused by RVO impair the photoreceptors in the outer retina. Sub retinal hemorrhage contains red blood cells is observed in eyes with macular edema associated with RVO[9, 10]. Blood in the sub retinal space may be harmful to photoreceptors, especially in eyes with AMD or retinal arterial macroaneurism[11]. In eyes with Ischemic retinal disorders visual acuity is greatly decreased by the loss of inner retinal neurons such as bipolar and ganglion cells in the papillomacular bundle area, which transport visual signals received by the photoreceptors in the central fovea and are closely associated with central visual acuity. Visual prognosis in eyes with CRAO is generally far worse than in those with BRAO[12]. Anti-vascular endothelial growth factor is a 40 kDa dimeric glycoprotein that is produced by hypoxic stimulation in different cells of the retina, vascular endothelium, retinal pigment epithelial cells, and Muller cells[1]. Anti-vascular endothelial growth factors (anti-VEGF) have revolutionized the management of retinal diseases. Bevacizumab (Avastin) was first VEGF-A inhibitor approved by the US Food and Drug Administration (FDA) in 2004 for the first-line treatment of metastatic colorectal cancer. Pegaptanib (Macugen) and Ranibizumab (Lucentis) were approved in 2004 and 2006, respectively. Ranibizumab was formulated for intraocular usage only. Bevacizumab allows better retinal penetration. Aflibercept (Eylea) is a recent anti-VEGF therapy approved in 2011. Indicated for treatment of neovascular age related macular degeneration (AMD), macular edema from RVO, diabetic macular edema(DME) and diabetic retinopathy. These anti-VEGF agents have shown significant gain in visual acuity and improvement in morphological

outcomes [13].

We reported a case of retinal disorder in which laser therapy was not effective. According to literature outcomes were not satisfactory in some cases. However, anti-VEGF agent shows significant improvement in visual acuity.

## CONCLUSION

To the best of our knowledge, from this case report and other literature it shows that anti-VEGF agents helped to improve good visual outcome. However, anti-VEGF treatment should always be considered as an option, especially in the presence of an experienced ophthalmologist, to ensure full recovery of the visual acuity with no further damage to the eye from this procedure. Further studies are needed to assess the effectiveness, safety and long term outcome of anti-VEGF treatment.

## REFERENCES

1. Aiello, L.P., et al., *Vascular endothelial growth factor in ocular fluid of patients with diabetic retinopathy and other retinal disorders*. N Engl J Med, 1994. **331**(22): p. 1480-7.
2. Ishikawa, M., et al., *Future therapies of wet age-related macular degeneration*. J Ophthalmol, 2015. **2015**: p. 138070.
3. Jampol, L.M., et al., *Anti-Vascular Endothelial Growth Factor Comparative Effectiveness Trial for Diabetic Macular Edema: Additional Efficacy Post Hoc Analyses of a Randomized Clinical Trial*. JAMA Ophthalmol, 2016. **134**(12).
4. Rein, D.B., et al., *The economic burden of major adult visual disorders in the United States*. Arch Ophthalmol, 2006. **124**(12): p. 1754-60.
5. Boyer, D.S., et al., *Anti-vascular endothelial growth factor therapy for diabetic macular edema*. Ther Adv Endocrinol Metab, 2013. **4**(6): p. 151-69.
6. Rosenfeld, P.J., et al., *Ranibizumab for neovascular age-related macular degeneration*. N Engl J Med, 2006. **355**(14): p. 1419-31.
7. Freund, K.B., S. Mrejen, and R. Gallego-Pinazo, *An update on the pharmacotherapy of neovascular age-related macular degeneration*. Expert Opin Pharmacother, 2013. **14**(8): p. 1017-28.
8. Brown, D.M., et al., *Sustained benefits from ranibizumab for macular edema following branch retinal vein occlusion: 12-month outcomes of a phase III study*. Ophthalmology, 2011. **118**(8): p. 1594-602.
9. Spaide, R.F., et al., *Optical coherence tomography of branch retinal vein occlusion*. Retina, 2003. **23**(3): p. 343-7.
10. Muraoka, Y., et al., *Branch retinal vein occlusion-associated subretinal hemorrhage*. Jpn J Ophthalmol, 2013. **57**(3): p. 275-82.
11. Hochman, M.A., C.M. Seery, and M.A. Zarbin, *Pathophysiology and management of subretinal hemorrhage*.

- Surv Ophthalmol, 1997. **42**(3): p. 195-213.
12. Yuzurihara, D. and H. Iijima, *Visual outcome in central retinal and branch retinal artery occlusion*. Jpn J Ophthalmol, 2004. **48**(5): p. 490-2.
  13. Cornel, S., et al., *Anti-vascular endothelial growth factor indications in ocular disease*. Rom J Ophthalmol, 2015. **59**(4): p. 235-242.