



MESENTERIC NEUROENDOCRINE TUMOR: A CASE REPORT

Sushil Bhandari¹, Hemraj Kandu², Lokraj Kandel³, Sunil Pradhan⁴, Sunil Pujara⁵ and Raj Gurung⁶

¹*The first affiliated Hospital of Yangtze University, Jingzhou, Hubei, P.R. China*

^{2,3,4,5,6} *Medical school of Yangtze University, Jingzhou, Hubei, P.R. China*

ABSTRACT

Neuroendocrine tumors (NETs) are neoplasms that arise from cells of the endocrine (hormonal) and nervous systems. Many are benign, while some are malignant. They most commonly occur in the intestine, where they are often called carcinoid tumors, but they are also found in the pancreas, lung and the rest of the body. Primary neuroendocrine tumor of the mesentery is very rare. More than 90% of gastrointestinal neuroendocrine tumors are located in the appendix, small intestine and rectum.

We present a case of very rare primary neuroendocrine tumor of mesentery in a 54 years old female and discuss imaging feature and the histopathological data.

Keywords: Neuroendocrine tumor (NET), Mesentery, Computed Tomography.

INTRODUCTION

Neuroendocrine tumors (NETs) originate from neuroendocrine cells, which are widely distributed throughout the body. They secrete different substances such as somatostatin, gastrin and adrenocorticotrophic hormone (ACTH). Excess amounts of these substances can lead to various clinical presentations depending on the substances produced by the tumor. Although there are many kinds of NETs, they are treated as a group of tissue because the cells of these neoplasms share common features, such as looking similar, having special secretory granules, and often producing biogenic amines and polypeptide hormones. [1]

The various kinds of cells that can give rise to NETs are present in endocrine glands and are also diffusely distributed throughout the body, most commonly Kulchitsky cells or similar enterochromaffin-like cells that are relatively more common in the gastrointestinal and pulmonary systems. [2] Histopathology examination showed well differentiated neuroendocrine tumor (G2).

Report of a case:

A 54-year-old female, presented at Jingzhou central hospital, Hubei PR China with a complaint of upper abdomen pain, fever, nausea and vomiting for 3 days. Patient also had history of palpable abdominal mass which had known occasionally and diabetes for 2 years. Physical examination revealed a huge oval and fixed mass with tenderness at the epigastric region. Serum Amylase and several tumor markers like CA125, CA199, AFP, CEA were normal. Gastroscopy and colonoscopy were also found to be normal. Color Doppler USG showed non echogenic mass of size 7.1 cm x 4.9cm with clear boundary. No blood flow signal was noted around the echo free area. Computed tomography (CT) scan demonstrated a 6x5 cm sized encapsulated mass with location in the transverse mesentery and anterior abdomen and attached to pancreas (fig: 1,4,5). No obvious enhancement noted with contrast (fig: 1,2).

Laparotomy was done with 15 cm longitudinal mid upper abdominal incision and abdominal cavity entered gradually. Liver color, size and texture were normal. Gall bladder size and appearance looked normal. No obvious congestion noted in stomach and small intestine. Abdominal mass of dark red color, 6 x 5 cm size was found in the transverse mesentery anterior abdomen and at the right side of pancreatic head. The tumor had complete capsule tightly adhered to omentum, pancreas and transverse mesentery. Tumor was resected carefully along with some attached part of transverse mesocolon and pancreas.

The specimen was encapsulated with massive hemorrhage, infection and necrosis. Histological examination showed tumor cells composed of homogenous small cells arranged in a trabecular pattern with the nucleus showing a round to oval shape, indistinct nucleoli, and coarsely granular chromatin pattern. There was no mitosis.

Histochemistry examination showed positive results for PCK, Vimentin, NSE, CD56, CAM 5.2 and CD10 (fig:6) while CR, EMA, Inhibin-A, CD99, WT-1, S-100, CgA, Syn, CD117, CD34, Dog-1, CD31, Desmin, FVIII were negative. And the Ki-67 index was about 5%.

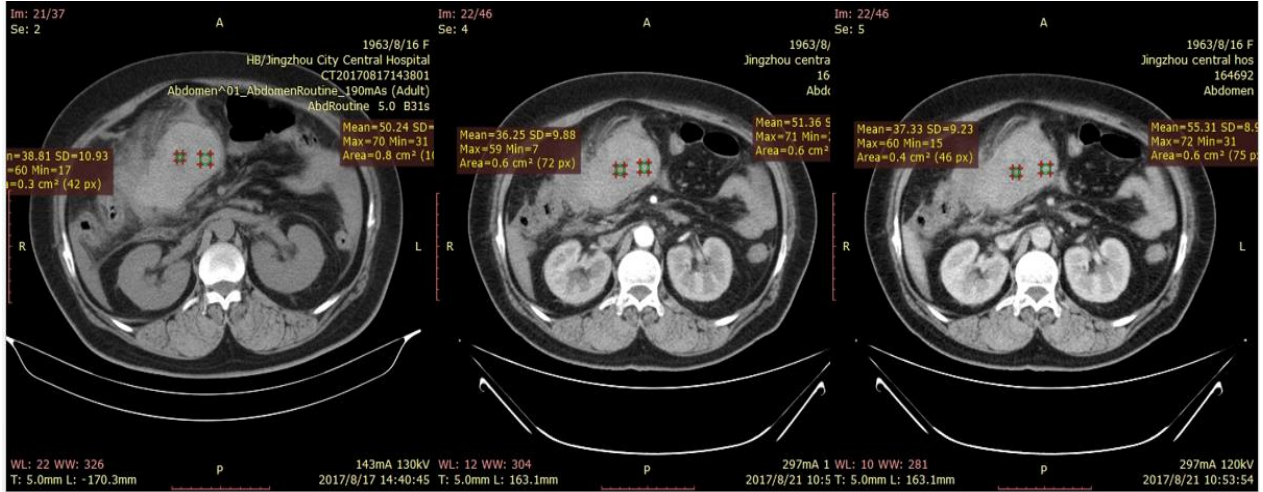


Figure 1: Plain CT

Figure 2: CECT Arterial

Figure 3: CECT Venous

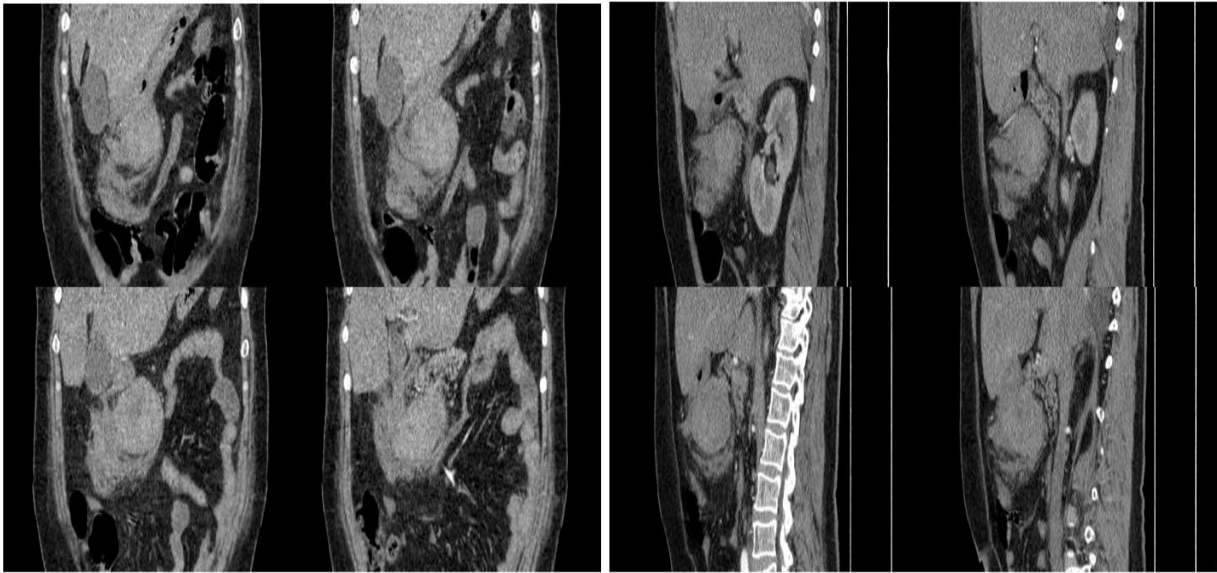
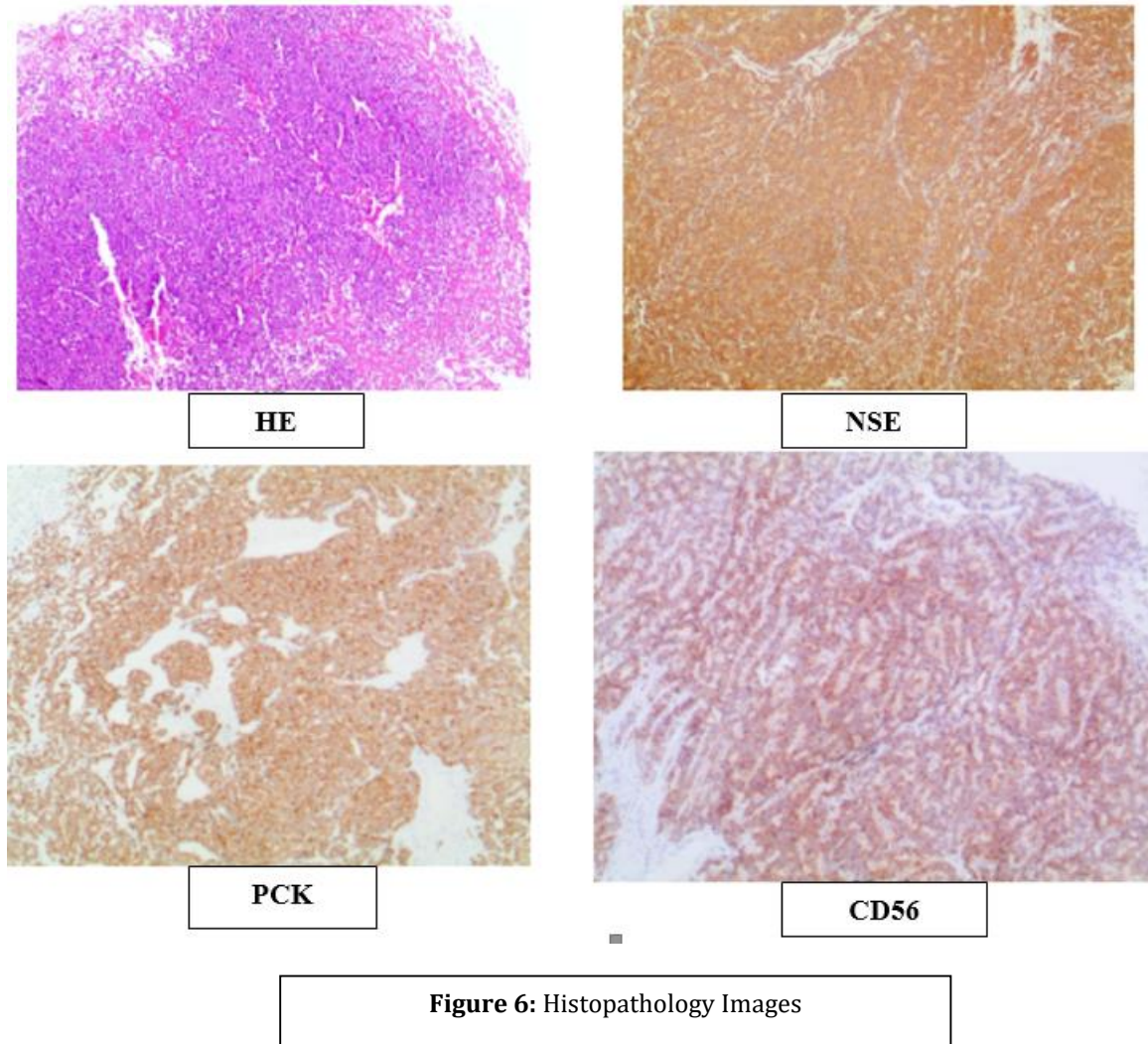


Figure 4: Coronal 3D reconstruction

Figure 5: Saggital 3D reconstruction



DISCUSSION

NETs originate from neuroendocrine cells, which are widely distributed throughout the body. They secrete various substances and hormones. These substances result in diverse clinical presentations. NETs most commonly involve the lungs and gastrointestinal system. They have also been reported in other sites such as the ovaries, prostate, lymph nodes and cervix. [3,4,5] Gastrointestinal NETs usually involve the small bowel, rectum, appendix and pancreas. Primary mesenteric NETs are extremely rare and very few cases of primary mesenteric involvement have been reported worldwide. [3,5,6] And carcinoid tumors arising in the mesentery are usually metastatic. Midgut carcinoid tumors commonly spread to the mesentery, reported as occurring in 40% to 80% of cases in various series. [7] On CT scan, mesenteric carcinoid tumors exhibit varying degrees of fibrosis, calcification, focal or diffuse neurovascular bundle invasion by the tumor or both mechanisms. [7]

The clinical presentation of these tumours depends on their location, and the types of hormones and substances they secrete.

To make the diagnosis of primary mesenteric NET, one must first rule out other primary sites by the use of CT, colonoscopy, small bowel series and scintigraphy. In our patient, color Doppler USG, abdominal CT

scan and surgical exploration exhibited a primary mesenteric tumour. Colonoscopy, Gastroscopy and several tumor marker could rule out other malignancies. NETs have specific immunohistochemistry features which are used for the confirmation of diagnosis. In our case, PCK, Vimentin, NSE, CD56, CAM 5.2, CD10 were positive, which confirmed the diagnosis of NET. And the Ki-67 positive index comes to 5% which makes our diagnosis of Transverse mesentery neuroendocrine tumor (G2).

Neuroendocrine lesions are graded histologically according to markers of cellular proliferation, rather than cellular polymorphism. The following grading scheme is currently recommended for all gastroenteropancreatic neuroendocrine neoplasms by the World Health Organisation. [8]

G	Mitotic count (per 10 HPF)	Ki-67 index (%)
GX	Grade cannot be assessed	
G1	< 2	< 3%
G2	2 to 20	3% - 20%
G3	> 20	> 20%

If mitotic count and ki67 are discordant, the figure which gives the highest grade is used.

In this case, the tumor originated from the transverse mesentery. But it was well encapsulated and free from the small intestine and stomach. At the time of surgery, whole abdominal cavity especially the entire small bowel was meticulously inspected and no evidence of tumor mass or enlarged lymph node was found. There was no evidence of tumor anywhere else in the abdomen including the liver and other solid organs. So, it may be a primary mesenteric NET.

Several issues help define appropriate treatment of a neuroendocrine tumor, including its location, invasiveness, hormone secretion, and metastasis. Treatments may be aimed at curing the disease or at relieving symptoms (palliation). Observation may be feasible for non-functioning low grade neuroendocrine tumors. If the tumor is locally advanced or has metastasized, but is nonetheless slowly growing, treatment that relieves symptoms may often be preferred over immediate challenging surgeries. Intermediate and high grade tumors (noncarcinoids) are usually best treated by various early interventions (active therapy) rather than observation (wait-and-see approach). [9] This case shows a rare large primary mesenteric NET, at laparotomy careful surgical excision of the tumor was done.

CONCLUSION

We are hereby reporting a case of a primary neuroendocrine tumor at the transverse mesentery which is extremely rare and very few cases have been reported worldwide. After a thorough investigation and ruling out other possible primary sites, we could confirm mesentery can be the primary site for neuroendocrine tumor and can be surgically excised.

REFERENCES

1. Ramage JK, Davies AH, Ardill J, et al. (June 2005). "Guidelines for the management of gastroenteropancreatic neuroendocrine (including carcinoid) tumours" (http://gut.bmj.com/cgi/content/full/54/suppl_4/iv1).
2. Liu Y, Sturgis CD, Grzybicki DM, et al. (September 2001). "Microtubule-associated protein-2: a new sensitive and specific marker for pulmonary carcinoid tumor and small cell carcinoma" PMID 11557784 (<https://www.ncbi.nlm.nih.gov/pubmed/11557784>).
3. Fasshauer M, Lincke T, Witzigmann H et al. Ectopic Cushing syndrome caused by a neuroendocrine carcinoma of the mesentery. *BMC Cancer* 2006; 6: 108.
4. Koch CA, Azumi N, Furlong MA et al. Carcinoid syndrome caused by an atypical carcinoid of the uterine cervix. *J Clin Endocrinol Metab* 1999; 84: 4,209–4,213.
5. Kitchens WH, Elias N, blaszkowsky LS et al. Partial abdominal evisceration and intestinal autotransplantation to resect a mesenteric carcinoid tumor. *World J Surg Oncol* 2011; 9: 11.
6. Kimchi NA, Rivkin G, Wiener Y et al. Primary neuroendocrine tumor (carcinoid) of the mesocolon. *Isr Med Assoc J* 2001; 3: 288–289.
7. Karahan OI, Kahrman G, Yikilmaz A, Ozkan M, Bayram F. Gastrointestinal carcinoid tumors in rare locations: imaging findings. *Clin Imaging* 2006;30:278-82.
8. Bosman, Fred T.; Carneiro, Fatima; Hruban, Ralph H.; Theise, Neil D., eds. (2010). *WHO Classification of Tumours of the Digestive System* (4 ed.). Lyon: International Agency for Research on Cancer. pp. 13–14. ISBN 978-92-8322432-7.
9. Warner, R.R.P. (2005). "Enteroendocrine Tumors Other Than Carcinoid: A Review of Clinically Significant Advances". *Gastroenterology*. 128 (6): 1668–84. doi:10.1053/j.gastro.2005.03.078 (<https://doi.org/10.1053/j.gastro.2005.03.078>). PMID 15887158.