



PULMONARY CAVERNOUS HEMANGIOMA (PCH): A CASE REPORT

Dr. Dipak Chaudhary*, Prof. Dr. Huang Jinbai and Prof. Dr Run Boxu

Department of Radiology, Clinical College of Yangtze University, The first affiliated Hospital of Yangtze University Jingzhou, Hubei Province, P.R. China

ABSTRACT

We report a rare case of pulmonary cavernous hemangioma in a 58-year-old male. A computed tomographic (CT) scan of the chest showed an ill-defined mass in the right upper lobe. Thoracoscopic assisted resection of upper and lower lobe of the right lung was done and postoperative pathological examination revealed cavernous hemangioma. We reviewed the clinical features, CT findings and therapeutic methods of hemangioma.

Keywords: pulmonary cavernous hemangioma, thoracoscopic resection,

INTRODUCTION

Hemangioma is among the most frequent tumors to involve the soft tissues. Cavernous hemangiomas are benign vascular tumours rarely described in the lungs. Symptoms include respiratory distress, cardiac failure and massive haemoptysis, but they are mostly asymptomatic. These are most commonly seen in the head and neck region in childhood; however, cases involving the lungs multiple pulmonary cavernous hemangiomas (PCH) have been reported in both adults and children, but rarely. PCH should not be overlooked in cases where multiple lung nodules are detected radiologically.

CASE REPORT

A 58 years male patient, Mr. Zhou Shaorong came to our hospital in the department of internal medicine with the complaints of chest pain, mild cough, difficulties in breathing and occasional blood in the sputum.

On past history, there is no any history of hypertension, Asthma, diabetese mellitus, heart diseases, tuberculosis, hepatitis and any other infectious disease.

He denied history of drugs and food allergy. There is no any history of surgical trauma and blood transfusion. Vaccination history is unknown.

On physical examination, patient has normal face, cooperative, oriented to time place and person. His blood pressure was 136/88 mm of hg, temperature 36.5°C, pulse 50 beats/min., respiratory rate 20 beats/min. no pallor, non-icteric, non-anaemic, superficial lymphnodes were not palpable. On chest examination, there was normal breath sound with no any added sounds, heart rate and rhythm was within normal limit and pathological murmer was absent. On examination of abdomen, it was soft, non-tender, not distended and rebound tenderness was absent. There was no any palpable mass.

On neurological examination physiological reflex were intact and pathological reflex was non elicited.

Chest CT was performed on which there was a single ill-defined nodule with ground glass opacification on the upper part of right lung (Fig 1). As there were few spiculations seen with the nodule, malignancy was suspected.

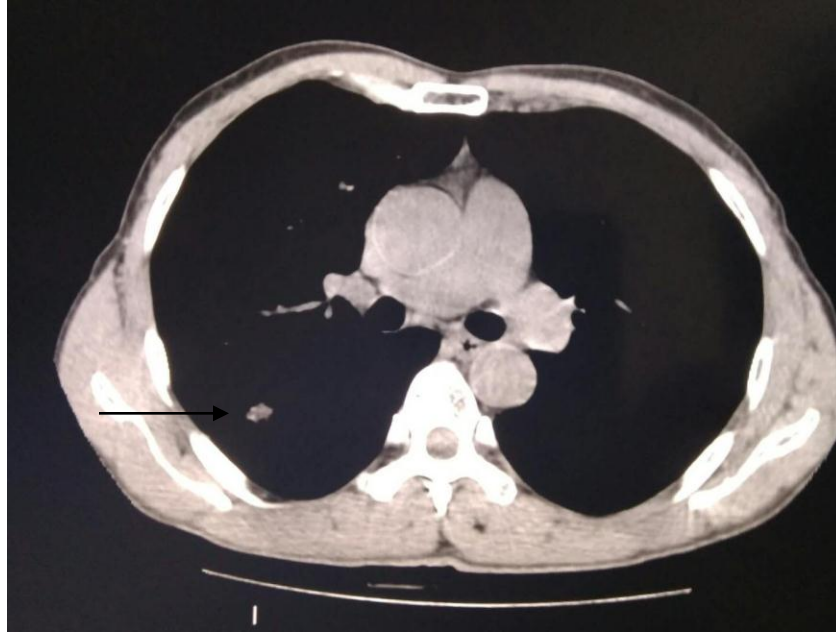

Figure 1: Chest axial CT in lung window setting showing ill-defined nodule with ground glass appearance on right upper lung.

Informed consent for the resection of the mass was taken from the patient. Then, Thoracoscopic assisted resection of the upper and lower lobe of the right lung was done. The size of the mass was found to be about 1.0*1.0cm and was lying between the upper and middle lobe of the right lung. So, partial resection of upper lobe and lower lobe mass was done. The specimen was sent for histopathology which confirmed the mass to be benign. During surgery 1500ml blood loss, blood transfusion 600ml was done, no blood transfusion reaction, the operation was successful and patient was shifted in postoperative recovery room.

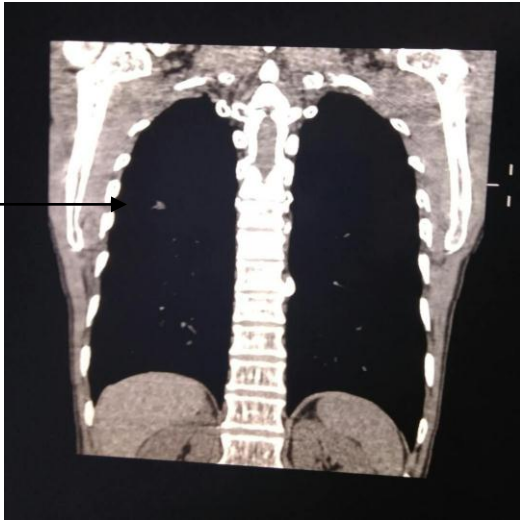


Figure 2: Coronal view of chest CT showing ill-defined nodule with ground glass appearance in the lower part of upper lobe of right lung.

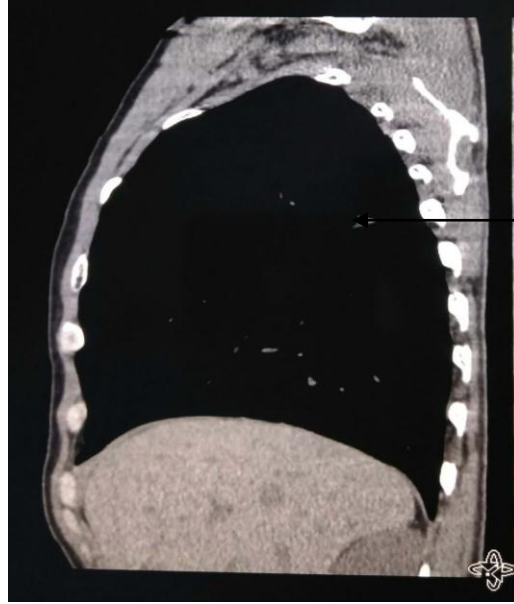

Figure 3: Sagittal view of chest CT showing ill-defined nodule with ground glass appearance in the posterior lower part of upper lobe of right lung.

Post-operative pathological diagnosis was (right upper) pulmonary cavernous hemangioma.

Immunohistochemistry: TTF-1(-), napsin A(-), CD34(+), D2-40(+), CD31(+)

DISCUSSION

Benign lung tumors represent 2–5% of primary lung neoplasm with hamartoma making up the vast majority of cases. Cavernous hemangiomas of the lung, on the other hand, are exceedingly rare. Arrigoni et al. reported only one pulmonary hemangioma case out of 130 benign lung tumors[1]. A review of the literature reports that PCHs affect a wide age range (7–84) [2]. A PCH may be localized or diffuse. Clinical manifestations are dependent on the lesion's location, number, and size. Some patients present clinical respiratory distress, cyanosis, hemoptysis, and even heart failure. Some patients show no apparent adverse symptoms even after death resulting from other causes [3].

PCHs may involve the parenchyma and the airway. Airway PCHs are rare but may be life-threatening as a result of their potential for airway obstruction or fatal hemoptysis. In the case reported here, PCHs invaded the large airway. If the lesions break through the mucous layer, there will be hemoptysis, even leading to lethal blood aspiration [4]. Generally, most of PCHs are solitary lesions and there have been no radiological characteristic findings. In most of these cases, surgical biopsies have been performed in order to

determine the presence of metastatic lung cancer. As of yet, there have been no radiological characteristic findings and most of the cases have shown solitary well-defined small nodule that reach into the arteries of multiple lung fields. Macroscopically, PCH lung nodules lacking capsules seem hemorrhagic and, histologically, they are composed of dilated vascular spaces lined by flattened bland cells. The definitive diagnosis of PCH can be made by histopathologic examination. Cavemous hemangiomas are characterized by large, dilated vascular spaces interposed with various stromal elements such as fat, myxoid fibroblastic proliferation, and fibrous tissue. The abnormal vessel agglomeration is sharply defined but not encapsulated; it may be accompanied by intravascular thrombosis or dystrophic calcification [5].

Evidence indicates that the increased expression levels of vascular endothelial growth factor and platelet-derived growth factor may be associated with PCH [6]. The histological features of PCH are the proliferation of capillaries within the alveolar walls, as well as muscularization of arterioles and medial hypertrophy of muscular pulmonary arteries. Therefore, PCH causes pulmonary hypertension [7].

The management of PCH varies depending on the severity of symptoms and the location and extent of the lesions. A solitary PCH should be treated with surgical excision; the impossibility of ruling out malignancy is the more common criteria for surgical resection. For multiple PCHs, local resection is rarely used; surgical procedure usually is just for pathologic diagnosis. Endoscopic treatment is suitable for airway PCH. Glade and colleagues [8] reported endoscopic management of venous malformations using a neodymium-doped yttrium aluminum garnet laser, which appeared to be both effective and relatively safe. Embolization may be a good method for some vascular malformations, just as with pulmonary arteriovenous fistula, although PCHs are a variant of slow-flow pulmonary venous malformations and it is difficult to locate the target vessels.

CONCLUSION

In summary, PCHs are extremely rare. They can be asymptomatic or can present with life-threatening symptoms. The clinical features are not well revealed. For a solitary PCH, surgical excision yields excellent outcomes, but for multiple PCHs, surgical intervention or close radiographic follow-up remains the treatment of choice.

REFERENCES

1. Arrigoni MG, Woolner LB, Bernats PE, et al. 1970. Benign tumors of the lung. *J. Thorac. Cardiovasc. Surg.* 60:589-599.
2. Ikeda M, Uno K, Hagiwara N, et al. 1983. Cavemous hemangioma of the lung: a case report and review of the Japanese literature. *Nihon Kyobu Geka Gakkai Zasshi* 31(8):1293-1297.
3. Mori, A., Obata, K., Tada, T. et al. A case of multiple cavemous hemangiomas of the lung. *Gan No*

Rinsho. 1985; 31: 1433–1438.

4. Ishikawa, T., Pollak, S., Perdekamp, M.G. et al. Hemorrhage from a cavernous hemangioma with fatal blood aspiration: a rare cause of sudden unexpected death. *Leg Med (Tokyo)*. 2010; 12: 308–312.
5. Fine, S.W. and Whitney, K.D. Multiple cavernous hemangiomas of the lung: a case report and review of the literature. *Arch Pathol Lab Med*. 2004; 128: 1439–1441 .
6. Fugo K, Matsuno Y, Okamoto K, Kusumoto M, Maeshima A, Kaji M, Takabatake H, Kondo H and Moriyama N: Solitary capillary hemangioma of the lung: Report of 2 resected cases detected by high-resolution CT. *Am J Surg Pathol*. 30:750–753. 2006.
7. Frazier AA, Franks TJ, Mohammed TL, Ozbudak IH and Galvin JR: From the archives of the AFIP: Pulmonary veno-occlusive disease and pulmonary capillary hemangiomatosis. *Radiographics*. 27:867–882. 2007.
8. Glade, R., Vinson, K., Richter, G. et al. Endoscopic management of airway venous malformations with Nd:YAG laser. *Ann Otol Rhinol Laryngol*. 2010; 119: 289–293