



THE ROLE OF IMAGING IN DIAGNOSIS OF OSTEOMYELITIS: REVIEW ARTICLE

Dr. Sumendra raj pandey, Dr. liu pei wu and Dr. Nitesh raj pandey

*Department of nuclear medicine and medical imaging, clinical medical college of Yangtze university, Jingzhou
central hospital, province- hubei, PR china*

ABSTRACT

Osteomyelitis is an important cause of morbidity and mortality in children and adults. The pattern of manifestation varies and is dependent on the site of involvement, the initiating event, the infecting organism, and the acute or chronic nature of the illness. Early diagnosis and detection of osteomyelitis and differentiation of soft-tissue infection from bone involvement is a difficult clinical and imaging problem. Imaging plays a crucial role in establishing a timely diagnosis and guiding early management, with the aim of reducing long-term complications. Recognition of the imaging features of osteomyelitis requires a good understanding of its pathogenesis. Plain radiographs remain the initial imaging modality used in the diagnosis and differential diagnosis of osteomyelitis. However, with the advent of newer imaging techniques such as nuclear medicine, ultrasonography, computed tomography, and magnetic resonance imaging, a higher degree of accuracy in diagnosis and definition of the extent of the disease has been achieved. Our goal in this review is to outline the ability of various imaging techniques by comparing their strengths and weaknesses in the diagnosis of osteomyelitis.

Keywords: magnetic resonance imaging (MRI), computed tomography (CT), ultrasonography (USG), nuclear medicine

INTRODUCTION

Osteomyelitis is a bone infection, usually caused by bacteria, that can be either acute or chronic. This disorder usually occurs as a result of an infection in one part of the body that is transported through the bloodstream to a bone in a distant location. It is inflammation of the bone marrow secondary to infection, which can progress to osteonecrosis, bone destruction and septic arthritis. It is an important cause of permanent disability in both children and adults worldwide (1). Among children and teens, the long bones of the legs and arms are most frequently affected. In adults, osteomyelitis most often affects the vertebrae of the spine and/or the hips. Osteomyelitis has a bimodal age distribution with peak incidences in children under 5 and adults over 50 years of age (2). The typical clinical presentation of osteomyelitis with pain, erythema and oedema of the affected part is non-specific and can be caused by a multitude of other diseases(3). Poor feeding and irritability may be the only symptoms present in infants. Serum inflammatory markers may be normal, especially in neonates and patients with chronic osteomyelitis (4).

This article provides an overview of the imaging of osteomyelitis, focusing on the correlation between radiological features and the underlying pathological processes. The pathogenesis of acute and chronic osteomyelitis will be described, together with a summary of key age-related differences in the patterns of disease. This is followed by a review of the imaging features of osteomyelitis on plain radiography, magnetic resonance imaging (MRI), nuclear medicine, computed tomography (CT) and ultrasound. There will be a particular emphasis on MRI because it is the imaging modality of choice for the investigation of suspected osteomyelitis in current evidence-based guidelines (5).

PATHOGENESIS

Classical hematogenous spread occur in children 2-6 years of age.



Infection starts in metaphysis hair pin arrangement of metaphyseal blood vessels which are non-anastomosing terminal branches of nutrient artery and they twist in hairpin loops before entering large network of sinusoidal veins.



Host bone initiates inflammatory reaction in response to bacteria



Bone destruction and production of an inflammatory exudates and dead cells (pus)

Acute and chronic osteomyelitis:

Acute osteomyelitis In osteomyelitis secondary to haematogenous spread or direct inoculation, bacterial proliferation within the bone induces an acute suppurative response. There is accumulation of pus within the medullary cavity leading to raised intramedullary pressure and vascular congestion, which can disrupt the intraosseous blood supply. Reactive bone and hypervascular granulation tissue may form around the intramedullary pus, giving rise to a well-circumscribed intraosseous abscess, also known as a Brodie's abscess (5).

Chronic osteomyelitis If the acute infection is inadequately treated, there will be progression of disease to chronic osteomyelitis. The pathological features of chronic osteomyelitis are a result of osteonecrosis, caused by disruption of the intraosseous and periosteal blood supply during the acute stage of disease. A fragment of dead infected bone becomes separated from viable bone and is known as a sequestrum. The bacteria within the devascularised sequestrum are protected from antibiotics and the endogenous immune response, thus forming a nidus for chronic infection which may persist for many years (1). In an attempt to wall off the sequestrum, an inflammatory reaction characterised by osteoclastic resorption and periosteal new bone formation occurs. The sequestrum becomes surrounded by pus, granulation tissue and a reactive shell of new bone known as an involucrum. The involucrum may have a cloaca through which the pus or sequestrum can be discharged (5).

Plain radiography:

Plain radiography has low sensitivity and specificity for detecting acute osteomyelitis. As many as 80% of patients who present in the first two weeks of infection onset will have a normal radiograph (2). Bone marrow oedema, which is the earliest pathological feature, is not visible on plain films. The features of acute osteomyelitis that may be visible include a periosteal reaction secondary to elevation of the periosteum (figure1), a well-circumscribed bony lucency representing an intraosseous abscess (figure2) and soft tissue swelling. However, none of these findings are specific to osteomyelitis and can also be seen in stress fractures, bone tumours or soft tissue infections (6).

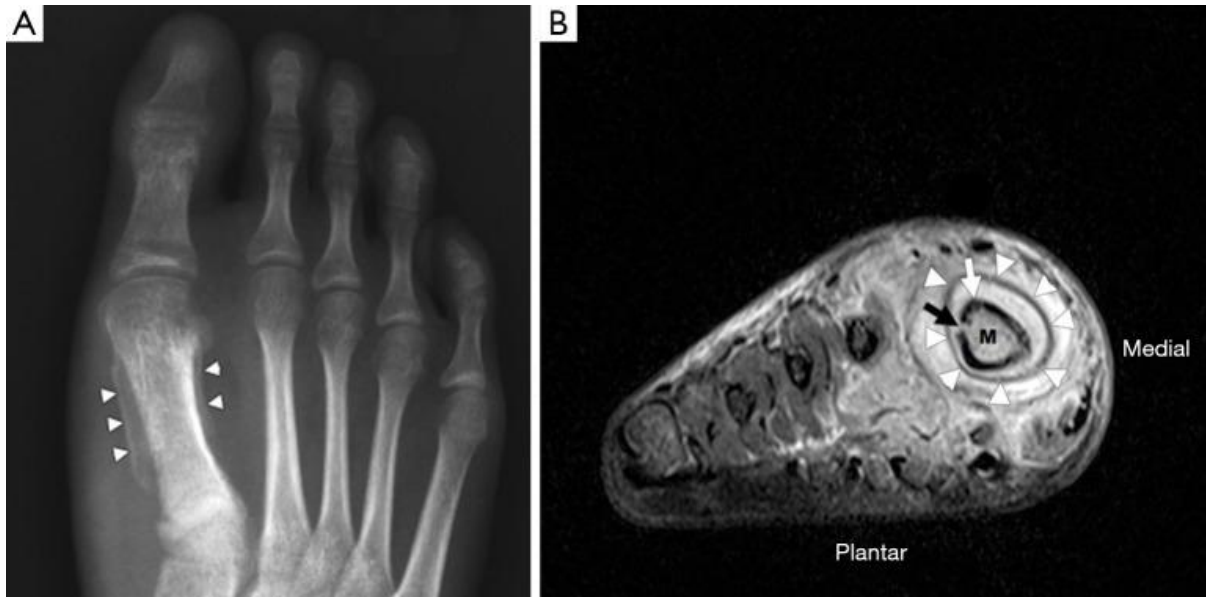


Figure 1 Osteomyelitis in the right foot of a 60-year-old male. (A) The dorso-plantar radiograph shows a periosteal reaction around the 1st metatarsal diaphysis (white arrowheads); (B) short axis coronal short-tau inversion recovery (STIR) image of the same patient demonstrating marked soft tissue oedema surrounding the 1st metatarsal. The periosteum (white arrowheads) is separated from the cortex (white arrow) by high signal material representing pus. There is a defect in the cortex (black arrow), known as a cloaca, that allows pus to drain from the medullary cavity into the subperiosteal space. Compared to the other metatarsals, the medulla (M) of the 1st metatarsal has high signal, consistent with bone marrow oedema.

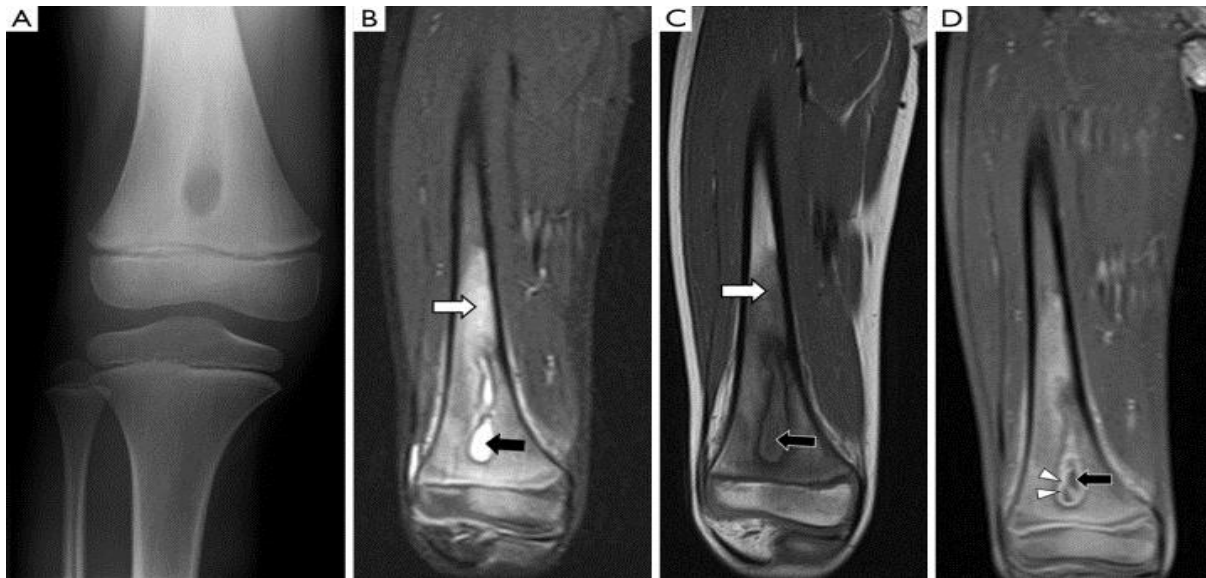

Figure 2 A 5-year-old girl with no history of trauma presents with pain and swelling in her right knee. (A) The anteroposterior radiograph shows a well-circumscribed lucent lesion with sclerotic margins in the right

distal femur metaphysis, suspicious for an intraosseous abscess; (B) coronal STIR image of the right femur shows that the lesion is within the medullary cavity and has high signal (black arrow). The bone marrow of the distal diaphysis and metaphysis has diffuse high signal (white arrow) compared to the mid-diaphysis, representing bone marrow oedema; (C) coronal T1W image shows that the intraosseous lesion has central heterogeneous low signal (black arrow). The bone marrow of the distal diaphysis and metaphysis has diffuse low signal consistent with oedema (white arrow). Note the distinct margin between normal and abnormal marrow, suggestive of bone marrow oedema due to osteomyelitis rather than reactive osteitis; (D) coronal fatsuppressed T1W image after administration of intravenous contrast shows that the lesion has central low signal (black arrow) and peripheral enhancement (white arrowheads). The central low signal represents pus and the peripherally enhancing areas represent hypervascular granulation tissue. This confirms an intraosseous abscess. Its location in the metaphysis is characteristic for haematogenous osteomyelitis.

In chronic osteomyelitis, a sequestrum may be visible on plain radiographs as a focal sclerotic lesion with a lucent rim (figure3). An involucrum can be seen as thickened and sclerotic bone surrounding the sequestrum. There can also be marked cortical destruction, a disorganised trabecular pattern and ill-defined bony lucencies. These findings of chronic osteomyelitis are best demonstrated with CT (7).

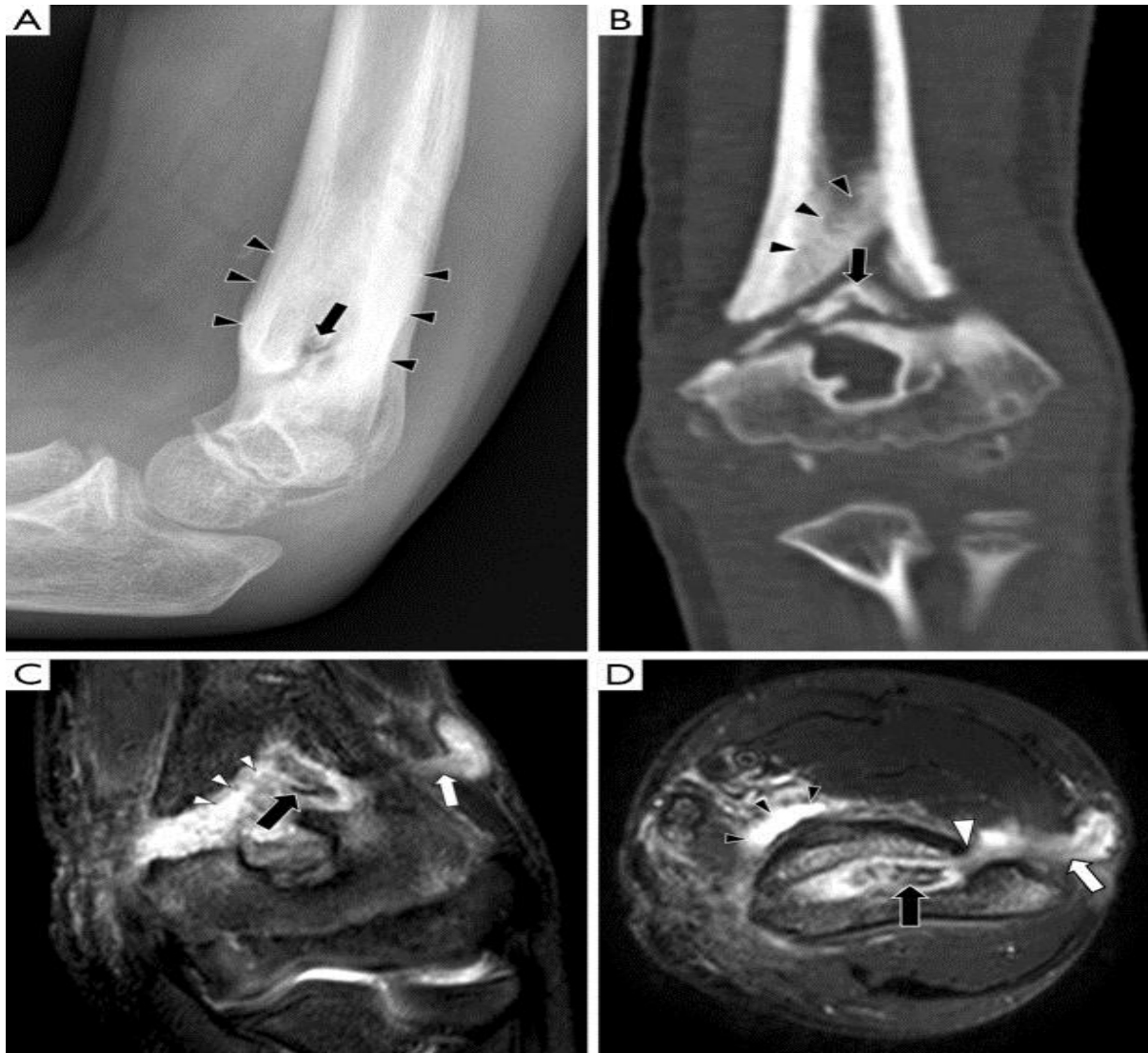

Figure 3 Chronic osteomyelitis in a 9-year-old boy with a non-united left distal humerus fracture. (A) The lateral radiograph shows marked periosteal thickening (black arrowheads) and a central sclerotic lesion with a lucent rim (black arrow); (B) coronal CT with bone windows shows a sclerotic fragment of bone which is separate from the rest of the humerus (black arrow), consistent with a sequestrum. Cortical thickening is also noted (black arrowheads); this represents an involucrum which is a result of periosteal new bone formation. These findings were not present on initial images taken at the time of the fracture; (C) coronal STIR image shows the low signal sequestrum (black arrow) surrounded by high signal pus and granulation tissue (white arrowheads). There is a sinus tract draining pus to the skin surface (white arrow); (D) axial fat-suppressed T2 image demonstrates that the pus surrounding the sequestrum (black arrow) communicates with the sinus tract (white arrow) via a cloaca (white arrowhead). There is also a soft tissue fluid collection anteromedial to the humerus (black arrowheads).

Despite its limitations, plain radiography should still be the first-line imaging test in suspected osteomyelitis, as it is useful for excluding other differentials such as fractures. Plain radiographs are also useful for assessing the progression of disease, by comparing changes seen on follow-up films with the initial radiograph (5).

Magnetic resonance imaging:

MRI has emerged as the imaging modality of choice for diagnosing osteomyelitis because of its excellent anatomical detail, high sensitivity for detecting early infection and lack of ionising radiation (7). The protocols and pulse sequences used in the evaluation of osteomyelitis will be described, followed by the MRI findings in acute and chronic osteomyelitis (table1).

Table 1

A summary of the key terms used to describe the pathological processes in osteomyelitis and their MRI signal characteristics

Key term	Pathological process	MRI signal		
		T1	T2	T1 + C
Bone marrow oedema	Accumulation of pus within the medullary cavity, leading to vascular congestion	Low	High	High
Intraosseous abscess	Formation of reactive bone and granulation tissue around intramedullary pus	Low	High	Peripheral enhancement
Subperiosteal abscess	Accumulation of pus beneath elevated periosteum	Low	High	Peripheral enhancement
Cloaca	A cortical defect that allows pus to drain between bone and soft tissue	Low	High	Low
Sinus tract	A channel, lined with granulation tissue, that allows pus to drain between bone and the skin surface	Low	High	Peripheral enhancement
Sequestrum	A separated fragment of necrotic bone that is surrounded by pus, granulation tissue and an involucrum	Low	Low	Peripheral enhancement

Magnetic resonance imaging (MRI) protocols:

In suspected osteomyelitis, the affected area is imaged in axial, sagittal and coronal planes using multiple pulse sequences. A pulse sequence is a set of parameters that highlights different tissue characteristics. The typical sequences used in the evaluation of osteomyelitis are as follows:

- ❖ T1-weighted (T1W) sequences provide good anatomical detail and enable delineation of the medulla, cortex, periosteum and soft tissues. On T1W images, fluid has low signal (appears dark), abscesses have low to intermediate signal and fat has high signal;
- ❖ Fluid-sensitive sequences include T2-weighted (T2W), fat-suppressed (FS) and short-tau inversion recovery (STIR) sequences. These all display fluid as high signal and are useful for detecting infection and inflammation, which cause an increase in tissue fluid content. Fat on T2W images has variable signal but is generally less bright than on T1W images. In fat-suppressed and STIR sequences, the signal from fat is decreased, increasing the visibility of inflammatory changes and fluid collections. Fat suppression can be applied to T1, T2 or proton density-weighted sequences. STIR sequences are more commonly used as the fluid-sensitive sequence in an osteomyelitis MRI protocol, as they are generally more sensitive than fat-suppressed sequences in demonstrating fluid;
- ❖ Proton density-weighted (PD) sequences are intermediately weighted between T1 and T2. PD images provide good anatomical detail but with less tissue contrast compared to T1W images (8).

Findings:

Bone marrow oedema is the earliest feature of acute osteomyelitis seen on MRI and can be detected as early as 1 to 2 days after the onset of infection (2). The normal marrow has high T1 signal due to fat within the medulla. In acute osteomyelitis, the bone marrow becomes congested with fluid and pus, producing low signal on T1W images and high signal on fluid-sensitive and post-contrast sequences (figure1,2).

An additional finding to note in acute osteomyelitis is periostitis, which is seen as elevation of the low-signal periosteum off the cortical surface and corresponds to the periosteal reaction seen on plain radiographs (figure2).

In chronic osteomyelitis The sequestrum can be difficult to visualise on MRI. It appears dark on all sequences because it is a fragment of necrotic bone that has very few protons available to produce an MR signal. However, the sequestrum is surrounded by hypervascular granulation tissue so it will have peripheral enhancement on post-contrast sequences, making it more conspicuous (figure 3) (7). The involucrum is seen as a thickened shell of bone around the sequestrum which displays either normal signal or oedema (8).

A cloaca can be seen in both acute and chronic osteomyelitis as a cortical defect that drains pus from within the medulla to the surrounding soft tissues. It is most easily seen on fluid-sensitive sequences because the draining pus within it will have high signal (figures 1,2)(8).

Differential diagnosis on magnetic resonance imaging (MRI):

Highly suggestive features of osteomyelitis on MRI are a peripherally enhancing intraosseous lesion, a non-enhancing sequestrum and a sinus tract. The presence of intra and extramedullary fat globules, seen as

foci of high T1 signal, is a less common finding of acute osteomyelitis but which is nonetheless highly suggestive (9). A proposed aetiology for the presence of these fat globules is increased intramedullary pressure causing extrusion of medullary fat. Bone marrow oedema and periostitis are more equivocal features which are often seen in other pathologies.

Depending on the clinical context, the following differentials may be considered when investigating suspected osteomyelitis:

- ❖ Reactive osteitis—reactive osteitis occurs secondary to trauma, cellulitis, pressure sores or inflammatory arthropathy and produces high marrow signal on fluid-sensitive sequences. To distinguish between reactive osteitis and osteomyelitis, the corresponding T1W images should be carefully scrutinised. In reactive osteitis, the marrow can have intermediate T1 signal or poorly demarcated areas of low T1 signal in a subcortical distribution. In acute osteomyelitis, the marrow is invariably of low T1 signal and appears darker and more well-demarcated compared to reactive osteitis, with an intramedullary distribution (10)
- ❖ Malignancy—on serial MRIs, osteomyelitis tends to cause more rapid destructive change compared to malignant bone tumours (7). Abscesses demonstrate peripheral rim enhancement whereas tumours usually enhance heterogeneously (11);
- ❖ Langerhans cell histiocytosis (LCH)—when it affects long bones, LCH tends to be centered on the diaphysis while haematogenous osteomyelitis tends to originate in the metaphysis (3);
- ❖ Osteoid osteoma—an osteoid osteoma is a benign tumour which is seen as an oval lucent lesion with a densely sclerotic center. It may appear similar to a sequestrum. Osteoid osteomas are usually round whereas sequestra are irregularly shaped. On post-contrast sequences, osteoid osteomas will enhance avidly while sequestra do not enhance. Osteoid osteomas are not associated with bone destruction or soft tissue inflammation (7);

Once osteomyelitis has been established as the most likely diagnosis based on the MRI findings and clinical history, treatment with empirical antibiotics would be commenced. If the patient fails to respond to antibiotics, a bone biopsy specimen may be required so that a definitive diagnosis can be made on microbiology and histology.

Nuclear medicine:

Nuclear medicine studies involve intravenous administration of a radionuclide, which emits radiation that is detected by a gamma camera. This allows assessment of abnormal bone metabolism, which in osteomyelitis manifests as areas of increased radionuclide uptake. The most commonly performed radionuclide studies for diagnosing osteomyelitis are the triple-phase, gallium and white cell scans, which are described individually in this section together with a newer technique, ¹⁸F-fluorodeoxyglucose positron

emission tomography (FDG-PET). In general, nuclear medicine studies have very high sensitivity in the detection of osteomyelitis and allow imaging of the whole skeleton to look for multiple sites of infection (12). However, nuclear medicine studies are limited by poor specificity and anatomical localisation. If there is an abnormal result, further confirmation with MRI or bone biopsy is usually required before a diagnosis of osteomyelitis can be established. Newer targeted radionuclides can increase the specificity of nuclear medicine studies and hybrid imaging techniques such as single photon emission computed tomography-CT (SPECT-CT) provide more anatomical information than conventional techniques (figure4) (13).

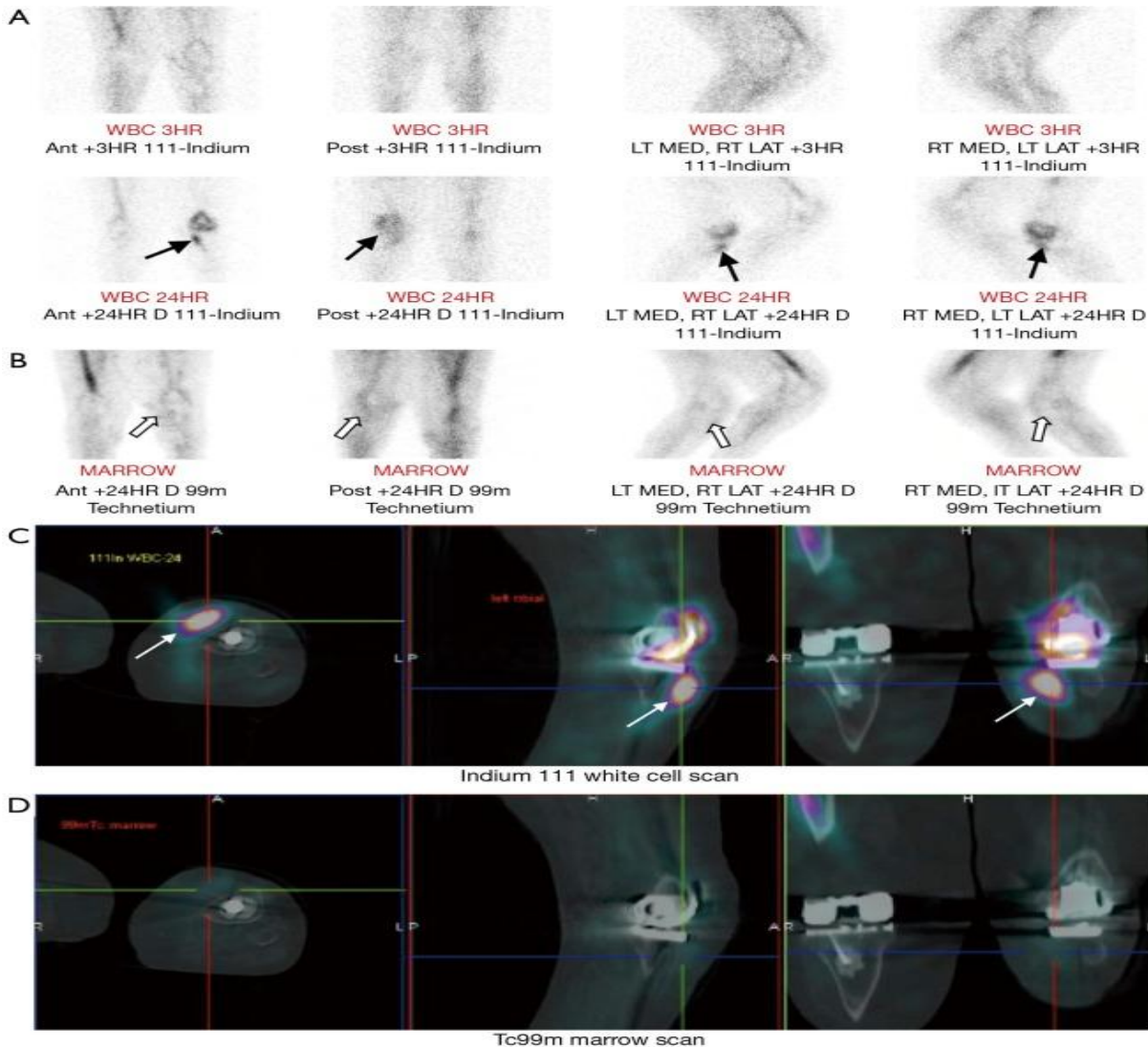


Figure 4 Suspected periprosthetic infection in a 72-year-old male with history of bilateral total knee replacements. A combined white cell and marrow scan was performed. (A) Indium 111-labelled white cell scan of the knees demonstrates accumulation of radiolabelled white cells in the left knee between the 3-hour and 24-hour images (black arrows); (B) the technetium 99m-labelled bone marrow scan provides a baseline

map of physiological white cell uptake. No tracer uptake is seen in the left knee (white arrows). The discordance between the white cell and marrow scan demonstrates that the white cell uptake is likely to be due to a focus of infection; (C,D) hybrid SPECT/CT imaging fuses functional and anatomical information to enable more accurate localisation of the focus of infection. The discordance between the white cell (white arrows) and marrow scans is again demonstrated, suggestive of periprosthetic infection.

Computed tomography:

Computed tomography is more widely available than MRI and image acquisition is less time-consuming. CT has good spatial resolution and can demonstrate clearly the anatomical relationship between areas of infection and important structures such as the spinal cord or major vessels. Hence, percutaneous aspirations and biopsies are often performed under CT guidance to avoid damage to these structures. CT has superior bony resolution to MRI and is better at demonstrating osseous changes such as cortical destruction, periosteal reactions and sequestrum formation. As with plain radiographs, the sequestrum on CT appears as a sclerotic lesion with a lucent rim (figure3). Intramedullary gas is an ancillary sign of osteomyelitis that is also best seen on CT (8).

However, the evaluation of osteomyelitis with CT is limited by its poorer soft tissue resolution compared to MRI. CT is unable to demonstrate bone marrow oedema, which means that a normal CT does not exclude early osteomyelitis. Other limitations of CT are ionizing radiation exposure and image degradation by streak artefact when metallic implants are present (14). Despite these limitations, CT remains a useful alternative when MRI is unavailable or contraindicated.

Ultrasound:

Ultrasound is of limited use in the diagnosis of osteomyelitis, as it cannot assess bone. Ultrasound is also an operator-dependent technique and can be challenging with larger patients. However, it can be useful for detecting soft tissue or subperiosteal collections, especially in children, although an MRI will still be required for a more thorough assessment. Subperiosteal abscesses are seen on ultrasound as periosteal elevation with an underlying fluid collection. Soft tissue oedema is seen as areas of hypervascularity around the affected bone on colour Doppler (2). If a collection is seen, the dynamic nature of ultrasonography makes it useful for guiding needle aspiration figure 5 (15).

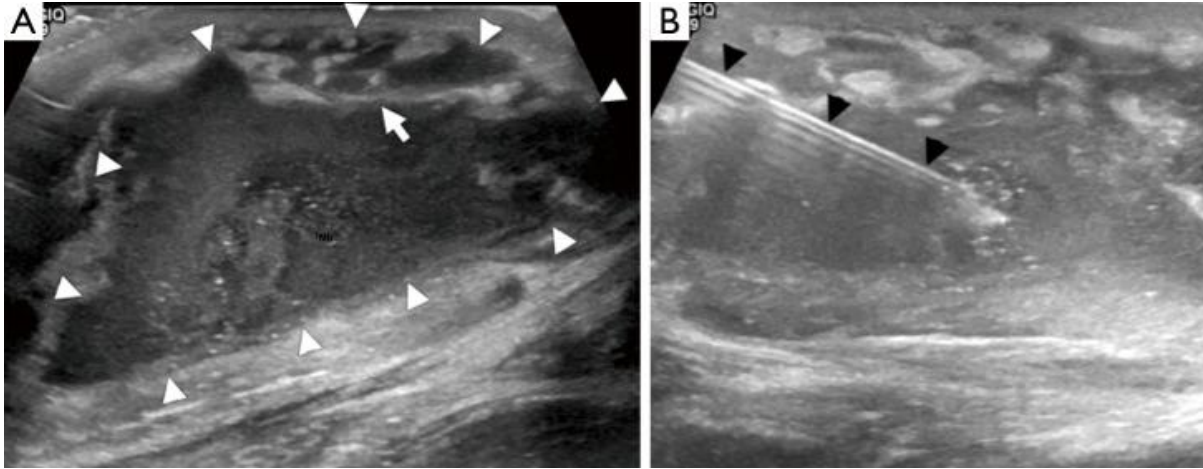


Figure 5 Osteomyelitis may be associated with soft tissue collections which can be seen on ultrasound. (A) Transverse section ultrasound image demonstrating a well-defined complex fluid collection which has an irregular thick wall (white arrowheads) and a hyperechoic septation (white arrow); (B) percutaneous needle aspiration of the fluid collection was performed (black arrowheads). Culture of the aspirate grew *Staphylococcus aureus*.

CONCLUSIONS

Imaging plays a central role in the diagnosis and management of osteomyelitis; a summary flow chart for imaging modality choice is provided in (figure6). Plain radiographs should ideally be obtained first to exclude other pathologies such as fractures. MRI is the best imaging modality for establishing the diagnosis of osteomyelitis as it can demonstrate bone marrow oedema, confirm the presence of abscesses and delineate extraosseous disease spread. If MRI is contraindicated or unavailable, nuclear medicine studies and CT are useful alternatives. The triple phase bone scan has high sensitivity for detecting acute osteomyelitis in non-violated bone. For violated bone, a combined white cell and bone marrow scan is the current study of choice. CT allows visualisation of osseous changes such as sequestrum formation and also for guiding aspiration and biopsy.

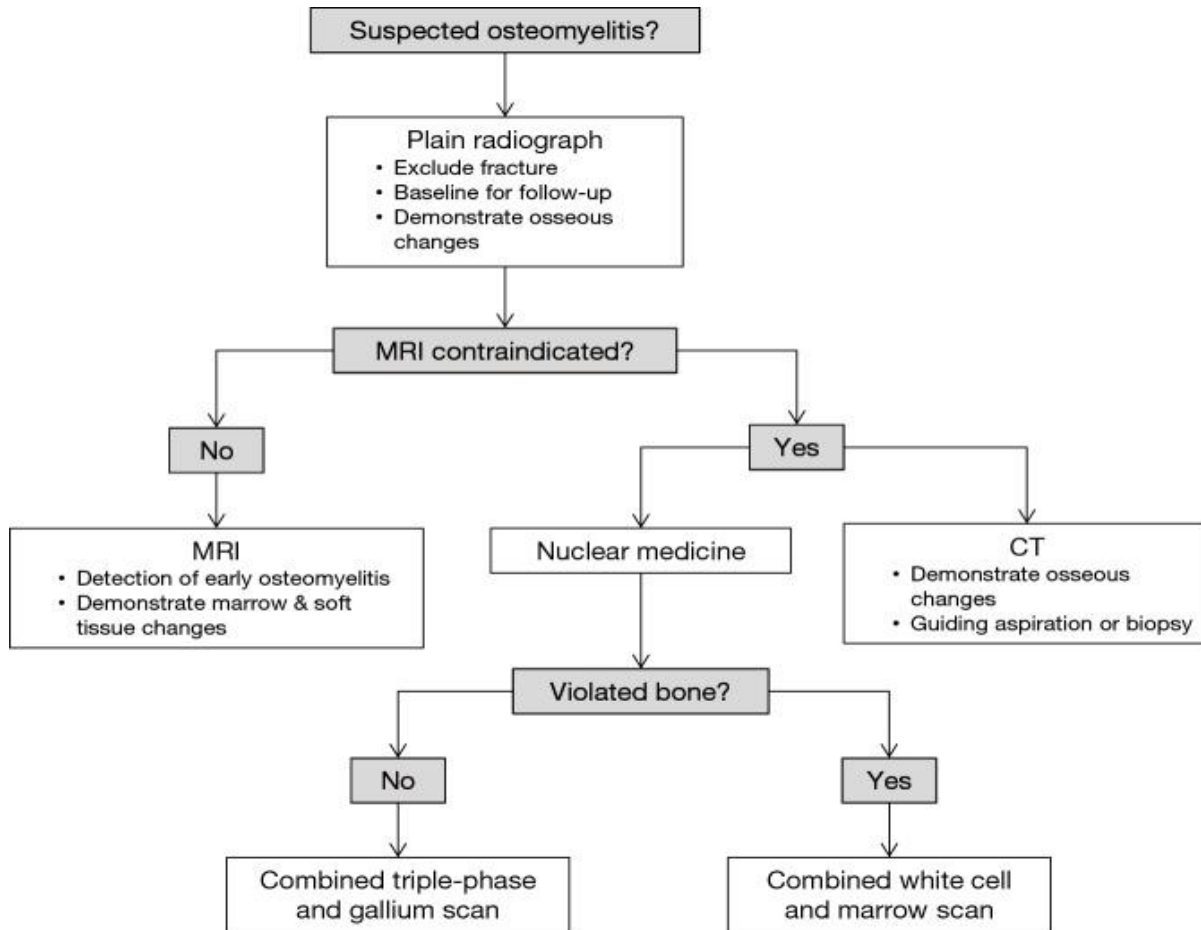


Figure 6 Flow chart for imaging modality choice in osteomyelitis. A plain radiograph should always be obtained first to exclude fractures. Unless contraindicated, an MRI should then be performed as it is the best currently available modality for establishing the diagnosis of osteomyelitis. If MRI is contraindicated, CT or nuclear medicine studies can be obtained, although these tests are of limited sensitivity and specificity compared to MRI.

REFERENCES

1. Lew DP, Waldvogel FA. Osteomyelitis. Lancet 2004;364:369-79. 10.1016/S0140-6736(04)16727-5 [Cross Ref]
2. Jaramillo D. Infection: musculoskeletal. Pediatr Radiol 2011;41 Suppl 1:S127-34. 10.1007/s00247-011-2001-y [PubMed] [Cross Ref]
3. Pugmire BS, Shailam R, Gee MS. Role of MRI in the diagnosis and treatment of osteomyelitis in pediatric patients. World J Radiol 2014;6:530-7. 10.4329/wjr.v6.i8.530 [PMC free article] [PubMed] [Cross Ref]

4. Offiah AC. Acute osteomyelitis, septic arthritis and discitis: differences between neonates and older children. *Eur J Radiol* 2006;60:221-32. 10.1016/j.ejrad.2006.07.016 [[PubMed](#)] [[Cross Ref](#)]
5. iRefer Guidelines. Making the Best Use of Clinical Radiology version 7.0.2.
6. iRefer Guidelines. Making the Best Use of Clinical Radiology version 7.0.2. Accessed 21st June 2015.
7. Manaster BJ. *Musculoskeletal Imaging: The Requisites*, 3rd ed. Philadelphia, PA: Mosby Elsevier
8. Rajashanker B, Whitehouse RW. Chapter 53: Bone, joint and spinal Infection. In: Adam A, Dixon AK, Gillard JH, et al. editors. *Grainger & Allison's Diagnostic Radiology*, 6th ed. New York, NY: Churchill Livingstone
9. Davies AM, Hughes DE, Grimer RJ. Intramedullary and extramedullary fat globules on magnetic resonance imaging as a diagnostic sign for osteomyelitis. *Eur Radiol* 2005;15:2194-9. 10.1007/s00330-005-2771-4 [[PubMed](#)] [[Cross Ref](#)]
10. Donovan A, Schweitzer ME. Use of MR imaging in diagnosing diabetes-related pedal osteomyelitis. *Radiographics* 2010;30:723-36. 10.1148/rg.303095111 [[PubMed](#)] [[Cross Ref](#)]
11. Shimose S, Sugita T, Kubo T, Matsuo T, Nobuto H, Ochi M. Differential diagnosis between osteomyelitis and bone tumors. *Acta Radiol* 2008;49:928-33. 10.1080/02841850802241809 [[PubMed](#)] [[Cross Ref](#)]
12. Mettler F, Guiberteau M. Chapter 8: Skeletal System. In: Mettler F, Guiberteau M, editors. *Essentials of Nuclear Medicine Imaging*, 6th ed. Philadelphia, PA: Saunders Elsevier, 2012:296-300.
13. Santiago Restrepo C, Giménez CR, McCarthy K. Imaging of osteomyelitis and musculoskeletal soft tissue infections: current concepts. *Rheum Dis Clin North Am* 2003;29:89-109. 10.1016/S0889-857X(02)00078-9 [[PubMed](#)] [[Cross Ref](#)]
14. Santiago Restrepo C, Giménez CR, McCarthy K. Imaging of osteomyelitis and musculoskeletal soft tissue infections: current concepts. *Rheum Dis Clin North Am* 2003;29:89-109. 10.1016/S0889-857X(02)00078-9 [[PubMed](#)] [[Cross Ref](#)]
15. Cardinal E, Bureau NJ, Aubin B, Chhem RK. Role of ultrasound in musculoskeletal infections. *Radiol Clin North Am* 2001;39:191-201. 10.1016/S0033-8389(05)70272-4 [[PubMed](#)] [[Cross Ref](#)]